

Palatal and Middle-Ear Myoclonus: A Cause for Objective Tinnitus

Carlos A. Oliveira, Jacinto Negreiros Jr., Iracema C. Cavalcante,
Fayez Bahmad Jr., and Alessandra R. Venosa

Department of Otolaryngology, Brasília University Medical School, Brasília–D.F., Brazil

Abstract: The cause of objective tinnitus provoked by palatal and middle-ear myoclonus may be identified by magnetic resonance imaging of the central nervous system in the Guillain-Mollaret triangle or it may be idiopathic. The idiopathic cases are rare. From the literature, one can perceive the following unanswered questions: (1) Are palatal and middle-ear myoclonus different entities or do they usually appear together? (2) Are the clicks being produced by the palatal myoclonus (walls of the eustachian tube slapping together) or by the tensor tympani muscle contractions or by both? (3) Is stapedius muscle myoclonus important in the production of the clicks? (4) What should be the treatment for palatal and middle-ear myoclonus? We present two cases of idiopathic palatal and middle-ear myoclonus and discuss these cases in light of the literature and of some ideas of our own.

Key Words: middle ear; myoclonus; objective tinnitus; palatal

ANATOMICAL AND PHYSIOLOGICAL FEATURES

The production of objective tinnitus by myoclonus has been reported in the literature as being related to palatal [1–4] or middle-ear myoclonus [5–9]. The tensor veli palatini muscle (TVPM) and the levator veli palatini muscle (LVPM) are involved in palatal myoclonus. The first muscle originates from the edge of the greater wing of the sphenoid bone, adjoining petrosphenoidal fissure, and lateral wall of the eustachian tube. Its tendon joins the palatal aponeurosis within the soft palate. It is supplied by the fifth cranial nerve. The second muscle arises from the inferior surface of the apex of the petrous bone medial to the eustachian tube, and its tendon merges with the upper and posterior surface of the palatal aponeurosis. Its nerve supply comes from the pharyngeal plexus and the eleventh cranial nerve.

The tensor tympani muscle (TTM) and the stapedius muscle (SM) are involved in middle-ear myoclonus.

The TTM arises from the cartilaginous part of the eustachian tube, the adjacent part of the greater wing of the sphenoid, and from its 20- to 25-mm-long semicanal; its tendon inserts in the neck of the malleus. Its nerve supply is the fifth cranial nerve. The SM arises from the pyramidal process, and its tendon inserts in the neck of the stapes. Its nerve supply is the seventh cranial nerve.

The TVPM increases tension in the soft palate and opens the eustachian tube when it contracts. The LVPM elevates the soft palate and probably assists in the opening of the eustachian tube by the TVPM. The TTM pulls the malleus medially, increasing tension in the tympanic membrane, and the SM pulls the stapes footplate away from the oval window.

This brief review of anatomy and physiology provides important notes: The TVPM and the TTM both are supplied by the fifth cranial nerve, and both have insertions in the cartilaginous portion of the eustachian tube. In contrast, the SM and the LVPM are supplied by different cranial nerves and by the pharyngeal plexus, and neither has insertions in the cartilaginous portion of the eustachian tube.

Reprint requests: Dr. Carlos A. Oliveira, SHIS QL-22 Conjunto-4 Casa-9, Brasília–D.F. 71650-145, Brazil. Fax: 55 61 346 3772; E-mail: oliv@abordo.com.br

This research was presented in part at the Twenty-Ninth Neurootological and Equilibriometric Society Congress, Bad Kissingen, Germany, March 14–17, 2002.

HISTORICAL PERSPECTIVE

In 1983, Rock [10] described some patients who were able to provoke objective tinnitus by forcefully closing

their eyelids (forceful eyelid closure syndrome). These patients had hearing losses in the lower frequencies, whereas hearing was normal in the higher frequencies. In 1995, the same author [11] studied 428 patients who had no complaint of tinnitus and found retraction of the manubrium and posterior middle one-third of the tympanic membrane in 107 patients (25%) under the microscope during forceful eyelid closure. He also found increased impedance at maximum compliance during forceful eyelid closure in 75% (321 patients).

In 1943, Smith [12] described one patient who was able to contract the TTM voluntarily. Audition to lower frequencies was diminished during TTM contraction. Deuschl et al. [1] stated the existence of two types of palatal myoclonus: *symptomatic*, in which a lesion in the brainstem or cerebellum is identified, and *essential*, in which no such lesion is documented. In 1999, Seidman et al. [2] described six cases of palatal myoclonus, five of which were due to lesions in the Guillain-Mollaret triangle identified by magnetic resonance imaging (MRI). This triangle is defined by the dentate nucleus, the red nucleus, and the inferior olive. The superior cerebellar peduncle joins the dentate and the red nuclei, and the olivodentate tract joins the dentate nucleus and the inferior olive. These authors believed that the great majority of palatal myoclonus cases have a documentable lesion in the aforementioned structures. Working with monkeys in 1984, Fitzgerald [3] showed that lesions in the inferior olivary tract caused palatal myoclonus.

Pulec et al. [4] studied two cases of palatal myoclonus. These authors showed that their patients heard sounds immediately after the onset of electrical activity in the region of the eustachian tube walls. They hypothesized that the noises were caused by the slapping of the eustachian tube walls as they closed. In 2000, Jero and Salmi [5] stated that palatal myoclonus may be idiopathic, but this is extremely rare. A cause can be identified in almost every case.

In 1994, Badia et al. [6] emphasized the great importance of distinguishing palatal from middle-ear myoclonus because the second disorder can be treated successfully by section of the TTM and SM tendons. In 1998, Bento et al. [7] described one case of objective, continuous, high-frequency tinnitus (8 kHz, 55 dB) that was cured by section of the TTM and SM tendons. Their hypothesis was that the continuous sound was caused by tetanic contractions of the TTM and SM muscles.

In 1974, Watanabe et al. [8] described eight patients who had previous facial nerve palsy and who experienced tinnitus caused by SM contractions during eye closure. Synkinesis would be the cause of the tinnitus.

In 1981, Klochoff [9] described patients with TTM contractions due to severe emotional distress and anxiety.

The symptoms were curable by relaxation techniques and section of the TTM tendon.

From these literature reviews, we derive several observations:

1. Most often, palatal myoclonus is related to documentable lesions in the central nervous system (Guillain-Mollaret triangle). Idiopathic cases are rare.
2. Still unclear is whether middle-ear and palatal myoclonus are different entities or usually appear together.
3. The origin of the sounds also is in doubt: Are they produced by the eustachian tube walls slapping together or by TTM contractions or by both, and is the SM important in the production of the tinnitus?
4. With all the aforementioned uncertainties, treatment of this condition is certainly open to discussion.

We present two cases of objective tinnitus caused by myoclonus, neither of which is accompanied by a documentable lesion in the central nervous system. We discuss these cases in light of the previously described literature and some ideas our own.

CASE REPORTS

Patient 1

A 40-year-old woman came to us complaining of bilateral clicks heard continuously in both ears and starting suddenly 4 years previously. Her husband could hear the clicks at night and was disturbed by them. The sounds were louder in the left side and could easily be heard by an examiner.

At otomicroscopy, we could see movement of the manubrium of the malleus and of the posterior quadrant of the tympanic membrane synchronous with the noises in both ears, although they were stronger in the left. Nasoendoscopy with a 4-mm zero-degree rigid endoscope (Storz Endoscopy of America Inc., Culver City, CA) showed movement of the soft palate synchronous with the sounds and revealed stronger pulses on the left side. The palate moved laterally and upward without closing the nasopharynx.

The results of neurological examination, MRI with gadolinium enhancement of the brain, and computed tomography of the temporal bones were normal. The audiometric results are shown in Figure 1. Tympanometry showed right and left middle-ear volume variations synchronous with the clicks. Stapedius reflex was present in the right ear and absent from the left ear.

We proceeded with exploratory tympanotomy of the left ear under local anesthesia. We could see the TTM

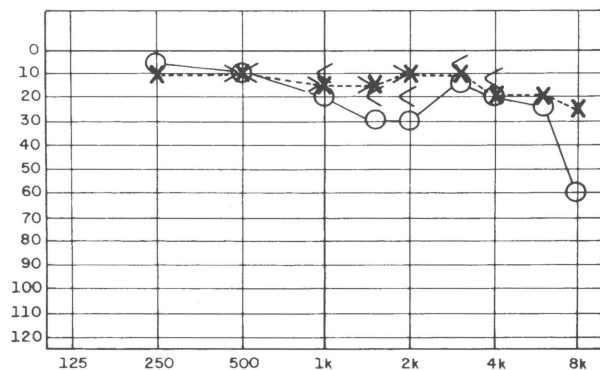


Figure 1. Patient 1 audiometry. Note the 50-dB hearing loss at 8 kHz in the right ear, probably unrelated to the tinnitus.

contracting rhythmically after exposure, but the SM was totally quiet. We sectioned the TTM tendon, after which the woman noticed remarkably diminished tinnitus on completion of the procedure; however, after 2 weeks, the symptom had returned. We explored the right ear and sectioned the TTM tendon. After the second procedure, the patient was much improved for 2 months, although she still could hear the clicks in both ears. Her husband no longer could hear the noises at night.

On follow-up, patient 1 stated that the clicks again were bothering her and, indeed, they could be heard by the examiner when he put his ear close to the patient's ear. At otomicroscopy, movement of the posterior quadrant of the tympanic membrane—but not of the manubrium of the malleus—could be seen in both ears. Tympanometry showed volume variations synchronous with the clicks in both ears (Fig. 2). The palatal movements were as strong as before at nasoendoscopy. The patient was placed on clonazepam for 2 weeks, after which she reported a decrease in the noises; however, she discontinued the medicine because of excessive drowsiness. When last seen 1 week before the writing of this article, she was on no medication and stated that the clicks were perfectly tolerable and that she did not wish further medication. Her husband was no longer complaining about the noises at night.

Patient 2

An 11-year-old boy came to us complaining of clicks in the left ear. His mother stated that he had had this symptom since he was a baby. The boy had many infections in this ear and eventually experienced a perforation of the tympanic membrane, which was central and dry at the time of examination. The noises were provoked by talking, swallowing, and sometimes by moving his neck. In the right ear, he also had clicks that were less intense and not as easily provoked by the

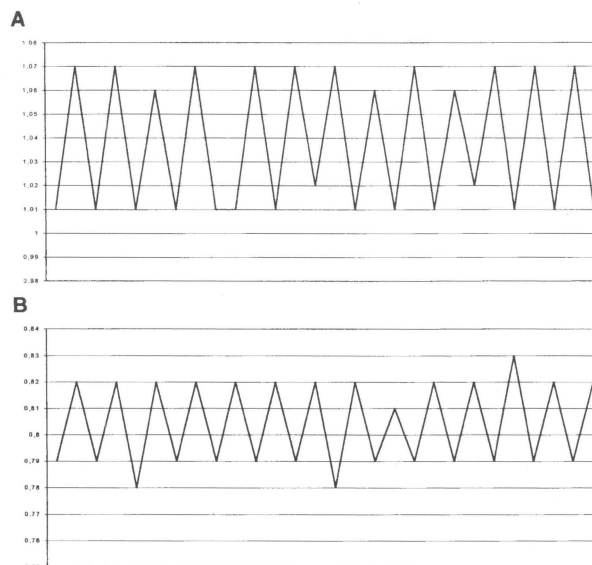


Figure 2. Patient 1 volume variation as registered by the impedance bridge. (A) Right ear. (B) Left ear. The tensor tympani muscle tendon has been cut on both sides; therefore, the volume oscillations are due to the tensor veli palatini muscle myoclonus opening the eustachian tube repeatedly. The intact tympanic membrane on both sides prevented any pressure variation large enough to be recorded.

aforementioned maneuvers. The noises in the left ear were easily heard by the examiner without getting close to the patient.

At otomicroscopy, no movement could be seen in either side, even though the clicks were evident. Impedanciometry revealed volume variations (Fig. 3A) and pressure variations (Fig. 3B) of the left middle ear synchronous with the clicks. The right ear was silent because the patient could not provoke the noises on this side.

The results of neurological examination and MRI with gadolinium enhancement were normal. Audiometry showed conductive hearing loss in the left ear compatible with the tympanic membrane defect (Fig. 4). Nasoendoscopy with the rigid 4-mm zero-degree endoscope (Storz) showed palatal movements (as described in patient 1) on both sides, although they were stronger on the left side. Also, the palatal myoclonus was synchronous with the clicks. Our plan is to perform a tympanoplasty in the left ear and to section the TTM tendon at the same time.

COMMENTS

In 1878, Politzer [13] was the first to describe this type of objective tinnitus. His impression was that movements of the tubal muscles caused the noises reported

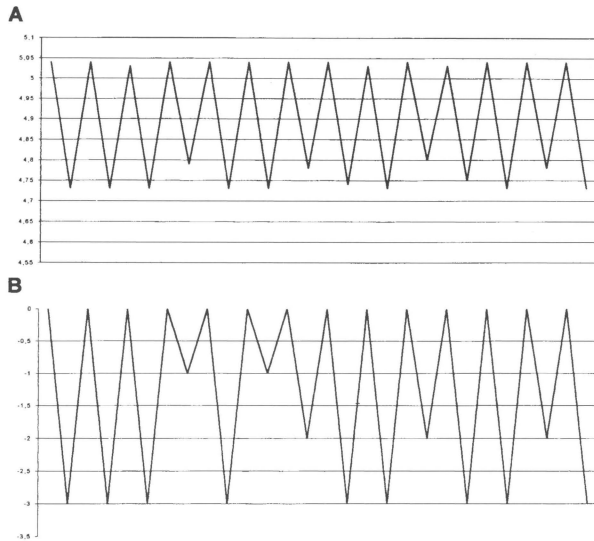


Figure 3. Patient 2. (A) Volume variation as registered at the impedance bridge in the left ear. (B) Pressure variation also in the left ear. As the left tympanic membrane had a large central perforation, these oscillations of volume and pressure are due to the tensor veli palatini muscle myoclonus opening the eustachian tube repeatedly.

in tinnitus. Since then, most reports on this subject refer to palatal myoclonus and follow Politzer's ideas [1-5, 11]. Few reports, however, refer to middle-ear myoclonus, and the source of the noises is said to be the TTM rhythmical contractions [6,11,12]. Some reports suggest simultaneous rhythmical contractions of the SM as part of middle-ear myoclonus. One report bases this assumption on the absence of stapedius reflex in two cases [14].

Some reports cite objective tinnitus associated with a previous episode of facial paralysis [8] and report high-frequency continuous objective tinnitus cured by

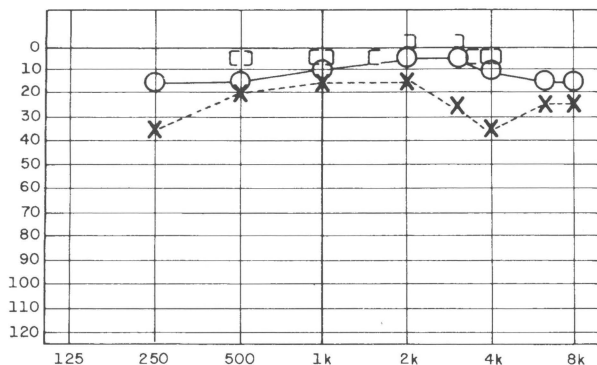


Figure 4. Patient 2 audiogram. Air-bone gap on the left is probably due to the tympanic membrane perforation and is not related to the tinnitus.

sectioning of the SM tendon [7]. These symptoms seem to be different from the clicking noise we have discussed and probably are associated with synkinesis of the facial muscles (tinnitus triggered by closing the eyes) and SM. Severe emotional distress and anxiety have been reported as causes of rhythmical TTM contractions and are said to be cured by relaxation techniques and section of the TTM tendon [9].

The first case that we presented herein clearly shows the occurrence of both palatal and TTM myoclonus synchronous with the noises. Section of both TTM tendons did not eliminate the clicking but rendered it much weaker and tolerable to the patient and her bed partner. However, also clear is that the palatal myoclonus is an important component of the clicks: After section of the TTM, we still observed wavy movement of the posterior quadrant of the tympanic membrane at otomicroscopy, which was confirmed by the impedance bridge. This outcome probably represents the repeated opening of the eustachian tube by the TVPM myoclonus, and the clicking probably originates from the slapping together of the tube walls when closing, as stated by Pulec et al. [4].

Stapedial reflex was present in the right ear of patient 1 and was absent in the left (worse) ear. However, during surgery, we watched the SM under the microscope for a long time and did not witness any contraction of this muscle. Possibly the absence of recordable reflex in the left ear was due to the strong rhythmical contraction of the TTM masking the reflex, but we cannot exclude the possibility of SM myoclonus not seen during surgery.

Further evidence of repeated opening and closing of the eustachian tube caused by the TVPM myoclonus is offered in our second case: Even though the tympanic membrane was perforated, we still could see rhythmical movements of the needle of the impedance bridge, probably indicating repeated pressure and volume changes in the middle ear (see Fig. 3). These changes were synchronous with the clicking.

Neither of our patients had any evidence of central nervous system disease. MRI results were normal in both. Patient 1 had a repeat examination 3 days before this writing, results of which showed no abnormalities in the Guillain-Mollaret triangle. Nonetheless, in more than 20 years of practice in Brazil, we have seen only two cases of idiopathic palatal and middle-ear myoclonus. They appear, therefore, to be rare.

CONCLUSIONS

Very likely, palatal (TVPM) and middle-ear (TTM) myoclonus occur together. Both muscles are supplied

by the fifth cranial nerve and belong to the same group of muscles. SM contribution to the clicks is possible but unlikely because it is supplied by a different cranial nerve (nerve VII) and it is a small muscle (four times smaller than the TTM semicanal). However, it may be the cause of objective tinnitus after facial paralysis.

What seems to be clear is that at least part of the noise is caused by the slapping together of the eustachian tube walls, as stated by Pulec et al. [4]. This would be caused by TVPM myoclonus. The TTM also has insertions in the cartilaginous eustachian tube and could contribute to tubal opening. Also clear is that TTM myoclonus produces noise in the middle ear when vibrating the ossicular chain. TTM section is effective in reducing the intensity of the clicking (as in patient 1).

From a practical standpoint, one must always search for both palatal (TVPM) and middle-ear (TTM) myoclonus in patients with tinnitus symptoms. They are very likely to occur together. Section of the TTM is an easy and safe procedure and may solve the problem (as in patient 1). If such a procedure is insufficient to cure the disorder, clonazepam might help but may not be tolerated and may lead to habit formation. Botulinum toxin injected in the TVPM certainly would work but might cause palatal dysfunction and would have to be repeated for a lifetime; the eustachian tube probably would malfunction as well.

Finally, one must always search carefully for central nervous system disease. It is our contention that most cases of myoclonus will have a cause somewhere in the Guillain-Mollaret triangle. Affected patients must be followed up closely, because such lesions may become apparent at a later date.

REFERENCES

1. Deuschl G, Mischke G, Schenck E, et al. Symptomatic and essential palatal myoclonus. *Brain* 113:1645–1672, 1990.
2. Seidman MD, Arenberg JG, Shirwany NA. Palatal myoclonus as a cause of objective tinnitus: A report of six cases and a review of the literature. *Ear Nose Throat J* 78:292–297, 1999.
3. Fitzgerald DC. Palatal myoclonus: Case report. *Laryngoscope* 94:217–219, 1984.
4. Pulec JL, Simonton KM. Palatal myoclonus: A report of two cases. *Laryngoscope* 71:668–670, 1961.
5. Jero G, Salmi T. Palatal myoclonus and clicking tinnitus in a twelve-year-old girl: Case report. *Arch Otolaryngol Head Neck Surg* 543(suppl):61–62, 2000.
6. Badia L, Parikh A, Brooks GB. Management of middle ear myoclonus. *J Laryngol Otol* 108:380–382, 1994.
7. Bento RF, Sanchez TG, Miniti A. Continuous high frequency objective tinnitus caused by middle ear myoclonus. *Ear Nose Throat J* 77:814–818, 1998.
8. Watanabe WI, Kamagami H, Tisuda T. Tinnitus due to abnormal contraction of the stapedius muscle. *J Otorhinolaryngol* 36:217–226, 1974.
9. Klochoff I. Impedance Fluctuation and a “Tensor Tympani Syndrome.” In RL Penha, W Pizarro (eds), *Proceedings of the Fourth International Symposium on Acoustic Impedance Measurement*. Lisbon: Universidade Nova de Lisboa, 1981:69–76.
10. Rock E. Forceful Eyelids Closure Syndrome. In *Proceedings of the Second International Tinnitus Seminar*. New York, 1983:165–169.
11. Rock E. Objective tinnitus and the tensor tympani muscle. *Int Tinnitus J* 1:30–37, 1995.
12. Smith A. Audiometric effects of voluntary contraction of the tensor tympani muscle. *Arch Otolaryngol* 68:369–372, 1943.
13. Politzer A. *Lehrbuch der ohrenheilkunde*. Stuttgart: IF Enke, 1878.
14. Virtanen HJ. Clinical records—objective tubal tinnitus: A report of two cases. *J Laryngol Otol* 97:857–862, 1983.