

# Persistent Continuous Dizziness: Pathophysiology and Treatment

Eiji Sakata, Kyoko Ohtsu, and Hideaki Sakata

Center for Vertigo, Disequilibrium, and Tinnitus Patients, Tokyo, Japan

**Abstract:** Persistent blurred vision and oscillopsia have a negative impact on quality of life, and the burden of these symptoms is more severe than that of rotationally vertiginous attack. We doctors should take patients' pain as our own and treat them accordingly. However, because these cases are rather rare in daily clinical experience, in reality we tend to treat these patients as neurosis cases and send the patients home without providing adequate care. We conducted a retrospective study involving 182 recently treated clinical cases and found that "jumbling of objects," which is thought to be caused by bilateral peripheral vestibular lesions, was more often observed in patients with central vestibular lesions. We named this the *pseudo-Dandy phenomenon*. In this study, we discuss the pathophysiology and treatment of this pseudo-Dandy phenomenon.

**Key Words:** pathophysiology; persistent dizziness; treatment

German painter Gerturud Richter expressed her vertiginous symptoms in her painting depicted in Figure 1. Richter did not paint many landscapes or still-life works. Rather, she is famous for her paintings of her own "Joy and Sorrow of Life." In this painting, completed in 1917, she captured a rotatory vertiginous attack, a disorder that she was experiencing at the time.

Richter's next painting was completed in 1924 (Fig. 2), by which time, her symptoms had progressed from occasional rotatory vertiginous attacks to constant dizziness or staggering vertigo. However, Richter's physician insisted that her vertigo was cured and would not listen to the patient. The physician even told Richter that she was just nervous, that she was experiencing climacteric disturbance, and that it was a psychogenic disorder. The doctor recommended that she consult a psychiatrist.

Persistent blurred vision and oscillopsia have a negative impact on quality of life, and the burden of these symptoms is more severe than that of a rotatory vertiginous attack. We doctors should consider a patient's pain as if it were our own and treat it accordingly.


However, because such cases are rather rare in daily clinical experience, in reality we tend to regard the patients as neurosis cases and send them home without providing adequate care.

We conducted a retrospective study involving 182 recently treated clinical cases and found that "jumbling of objects," which is thought to be caused by bilateral peripheral vestibular lesions, was more often observed in cases of central vestibular lesions. We named this phenomenon the *pseudo-Dandy phenomenon* [1,2]. In this study, we were interested in the pathophysiology and treatment of this pseudo-Dandy phenomenon.

## PSEUDO-DANDY PHENOMENON

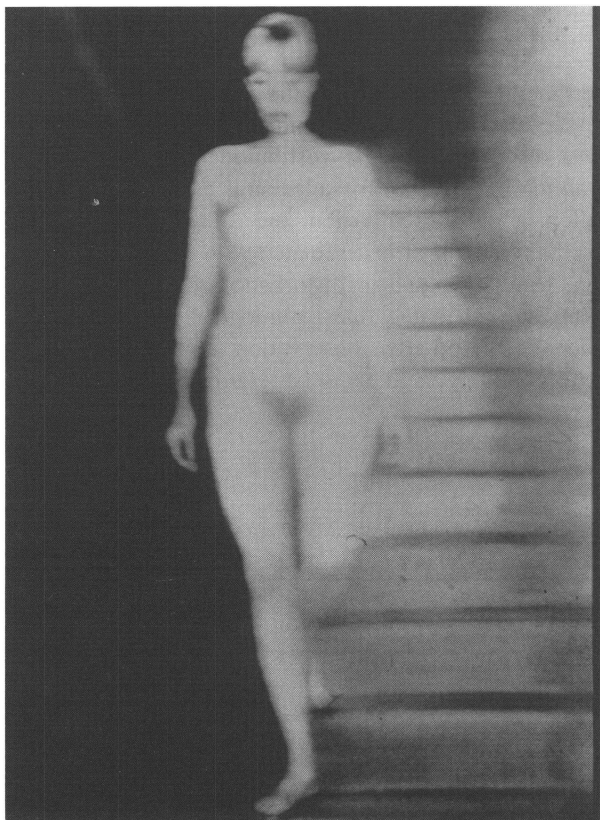
In 1928, Dandy [3–7] first described blurred vision, floating sensation, and oscillopsia experienced during walking by patients with advanced bilateral Ménière's disease. In 1954, Bluda (cited in Bender [8]) also noted this phenomenon in patients whose bilateral vestibular nerves had been cut off and proposed calling it the *Dandy phenomenon* after the physician who first described it. In 1975, Bender [8] reported this phenomenon in a case of bilateral labyrinthine destruction and called it the *jumbling phenomenon*. Since then, the phenomenon has become widely known and regarded as if it represents a syndrome typical of the loss of bilateral peripheral vestibular function.

Reprint requests: Prof. Dr. Eiji Sakata, Director, Center for Vertigo, Tinnitus, and Hearing Loss, Cent-Building 6F, Matsouka, Nishishinjuku 1-7-1, Shinjuku, Tokyo, Japan 160-0023. Fax: 0081 3 3340 1750.



**Figure 1.** Copy of an original painting by Richter (1917), depicting her perception of her vertigo. (Reprinted by permission.)

However, we reported in 1985 that caloric reaction is good in the presence of this syndrome; that the syndrome often is noted in the presence of a posterior fossa lesion as well; that some of the patients complaining of



**Figure 2.** Copy of an original painting by Richter (1924), depicting her perception of her persistent dizziness. (Reprinted by permission.)

the syndrome actually have acquired pendular eye movement; and that these patients are not given a proper diagnosis or treatment and are referred by almost all clinicians to psychiatric services on grounds of “unsteady dizziness,” “psychogenic reaction,” “fatigue,” or “autonomic nervous insufficiency.” Therefore, we proposed calling this condition the *pseudo-Dandy phenomenon* (Table 1) [1].

Here, we report the results of our examination of 182 patients who visited our clinic in the last 21 months because of the pseudo-Dandy phenomenon. Of these patients, 150 were confirmed, both by gross observation and by electronystagmography (ENG) examination, to have acquired pendular nystagmus.

The pseudo-Dandy phenomenon appears most markedly during walking, but it is also seen in a sitting position and sometimes in a lying position. As mentioned, some patients have pathological eye movement, and others have no pathological eye movement but have

**Table 1.** Various Names Applied to the Pseudo-Dandy Phenomenon, According to Symptoms Displayed

Term	Symptom	Study
Dandy	Ménière’s disease	Dandy, 1928
Dandy phenomenon	Bilateral vestibular nerve cut	Bluda, 1954
Jumbling phenomenon	Bilateral labyrinthine lesions	Bender, 1975
Pseudo-Dandy phenomenon	Peripheral vestibular lesions, cerebellar vermis lesion, midbrain pretectal lesion, other (posterior fossa lesions)	Sakata, 1985

Source: Adapted from Bender [8].

**Table 2.** Risk Factors for the Pseudo-Dandy Phenomenon

Characteristic	No. of Patients*
Gender	
Male	56
Female	124
Constitution	
Allergy	56
Hypotonia	38
Motion sickness	81
Intoxicant	
Hair cosmetics	58
SM, KM, organic solvent, etc.	34
Alcohol	7
Other risk factors	
Hyperlipidemia	44
Diabetes mellitus	24
Heart disease	63
Gout	4
Hypertonia, etc.	12
Nystagmus	
Sylvian aqueduct syndrome	69
Other posterior fossa lesion	38
Acquired pendular oscillation	
Observation	132
Electronystagmography	150

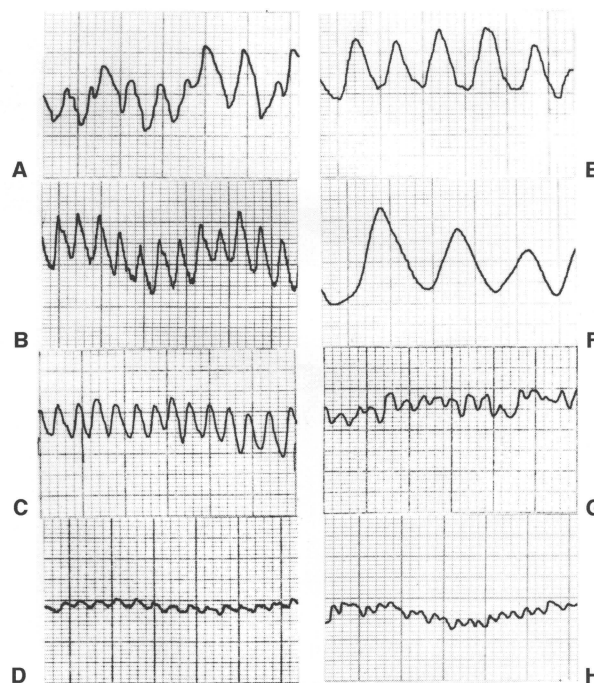
\*n = 182 of 3,950 cases, January 1995–September 1996.

pathological floating sensation. Table 2 lists the statistics for the 182 patients who developed the pseudo-Dandy phenomenon in the last 21 months. Various problems are highlighted, including constitution, intoxication with various drugs, and other risk factors. As shown in this table, these patients may be divided into three groups according to risk factors: those in one group have hypotonia, allergy, or motion sickness; those in the second group have organic solvent intoxication; and those in the third group have diabetes mellitus, hyperlipidemia, heart disease, gout, thyroid gland disease, or abnormal blood pressure.

Figure 3 shows ENG tracings of acquired pendular nystagmus. Panels A and B depict organic solvent intoxication; panel C reflects multiple sclerosis; and panel D is from a patient with nonhereditary sickle cell disease. Panels E and F depict vascular lesion, and panels G and H reflect hereditary sickle cell disease. Table 3 shows how acquired pendular nystagmus is variously named according to underlying diseases. Reports have been published by Guillain, Jung, Dichgans, Sakata, Lawrence, Aschoff, and Sakata et al. [1,2,9–12].

**Pathophysiology**

The pathophysiology of the pseudo-Dandy phenomenon does not seem to be monogenic. First, in the case of



**Figure 3.** Electronystagmographic tracings of acquired pendular nystagmus (acquired pendular oscillation).

peripheral vestibular lesion, the cause may be the phase discrepancy between body and ocular movement owing to a disturbance of the vestibuloocular reflex during walking. A posterior fossa lesion is associated with oscillopsia or blurred vision due to acquired pendular oscillation itself or is associated with exaggerated fixation oscillation due to disturbance of visual suppression. Further, some fine pathological eye movement, undetectable by gross observation or ENG using modern technology, is likely to be responsible.

**Table 3.** Acquired Pendular Nystagmus (Pseudo-Dandy Phenomenon)

Symptom	No. of Patients
No pathological eye movement	32
Acquired pendular oscillation	26
Acquired pendular oscillation of wandering type	74
Acquired pendular oscillation of wandering type + periodic eye movement	38
Unclassified	12
Total	182

Note: Compare acquired pendular oscillation of wandering type without pseudo-Dandy phenomenon, n = 115.

**Table 4.** Therapeutic Regimens

Regimen	Dosage
Regimen 1	
Clonazepam	0.9 mg three times daily after meals
Cinnarizine	150 mg three times daily after meals
Tofisopam	150 mg three times daily after meals
Regimen 2	
Imipramine hydrochloride	25 mg once daily before bedtime
Regimen 3	
Thyrotropin-releasing hormone + CDP-choline	1,000 mg intravenously once weekly

### Therapy

As shown in Table 4, we have been administering oral clonazepam, cinnarizine, and tofisopam three times daily and imipramine once before bedtime. In addition, we administered an intravenous injection of thyrotropin-releasing hormone (TRH) and CDP-choline once daily for 2 weeks. With this regimen, we have obtained satisfactory results. Not only has pathological sensation disappeared but even pathological eye movement has disappeared in some patients.

### REFERENCES

1. Sakata E, Ohtsu K. Recent development of the study on clinical significance of abnormal eye movement. *Auris Nasus Larynx (Tokyo)* 12:169–182, 1985.
2. Itoh Y, Sakata E, Ohtsu K. Electro-oculographical considerations on acquired pendular continuous oscillations of the eyes. *Neuroophthalmol Jpn* 4:314–321, 1987.
3. Dandy WE. Ménière's disease: Diagnosis and treatment. *Am J Surg* 3:693–698, 1933.
4. Dandy WE. Ménière's disease: Its diagnosis and a method of treatment. *Arch Surg* 16(6):1127–1152, 1928.
5. Dandy WE. Ménière's disease: Its diagnosis and treatment. *South Med J* 30(6):621–623, 1937.
6. Dandy WE. The Surgery of Ménière's Disease. In SJ Koptetzky (ed), *Surgery of the Ear*. New York: T Nelson and Sons, 1938:chapter 16.
7. Dandy WE. The surgical treatment of Ménière's disease. *Surg Gynecol Obstet* 71:421–425, 1941.
8. Bender MB. The Vestibular System. General Consideration. In RF Nauton (ed), *The Vestibular System*. New York: Academic Press, 1975:451–455.
9. Jung R. Eine elektrische Methode zur mehrfachen Registrierung von Augenbewegungen und Nystagmus. *Klin Wochenschr* 21–24, 1939.
10. Güttich A. *Neurologie des Ohrlabyrinthes*. Leipzig: Georg Thieme Verlag, 1944.
11. Szentagothai J. *Die Rolle der einzelnen Labyrinth-rezeptoren bei der Orientation von Augen und Kopf im Raume*. Budapest: Akademia Kiado, 1952.
12. v. Holst E. *Optische Wahrnehmungen, die wir selbst erzeugen—und ihre Bedeutung für unser Dasein*. Göttingen: Max-Planck-Gesellschaft zur Förderung der Wissenschaften e.V., 1956.