

# Medical Treatment of Otosclerosis: Rationale for Use of Bisphosphonates

**Kenneth Brookler**

*Neurotologic Associates, PC, New York, New York, USA*

**Abstract:** Otosclerosis is a bony dyscrasia characterized by histopathological findings of osteoclast production. Osteoclastogenesis explains the pathogenesis of otosclerosis. Basic science research in the experimental animal otic capsule has given insight into the process of evolution of otosclerosis. The normal otic capsule is preserved with very little bone turnover as a result of the production of osteoprotegerin (OPG) by the membranous inner ear that prevents the activation of osteoclasts. Animals genetically unable to produce OPG demonstrated the production of hearing loss and histopathology of the temporal bones consistent with that seen in otosclerosis. Applying the understanding of osteoclastogenesis to the treatment of otosclerosis has led to the clinical use of the class of drugs called *bisphosphonates*. The bisphosphonate group of drugs specifically targets osteoclasts by reducing production of osteoclasts and accelerating their early cell death. The rationale for use of bisphosphonates to treat the sensorineural hearing loss of otosclerosis is explained, with cases that illustrate the bisphosphonates treatment algorithms and the response to treatment.

**Key Words:** bisphosphonates; osteoclastogenesis; osteoprotegerin (OPG); otosclerosis; receptor-activator nuclear kappa ligand (RANKL)

Otosclerosis is a bony dyscrasia of the otic capsule [1,2]. In its active phase, it is characterized by histopathological findings of osteoclast production. The new investigative field of osteoclastogenesis has evolved, explaining the pathogenesis of otosclerosis [3–6]. Osteoclastogenesis explains the rationale for the use of bisphosphonates in the treatment of otosclerosis. Simple cartoons of osteoclastogenesis (the normal otic capsule, Fig. 1; otosclerosis, Fig. 2) are provided.

The normal otic capsule is preserved with very little bone turnover and is devoid of osteoclasts as a result of production of a cytokine osteoprotegerin (OPG) by the membranous inner ear. OPG attaches at the receptor-activator nuclear kappa (RANK) receptor of the macrophage to prevent its conversion to an osteoclast [7].

Research in animals genetically unable to produce OPG revealed hearing loss and histopathology of the temporal bones consistent with that seen with otosclerosis

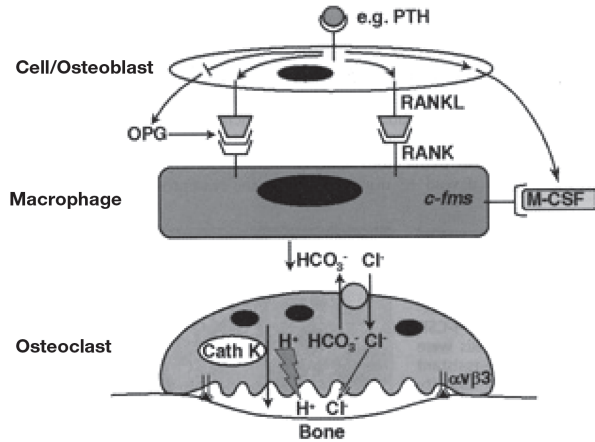
[8]. The active phase of otosclerosis is characterized by osteoclast activation as a result of inflammation [9–14]. Tumor necrosis factor alpha (TNF- $\alpha$ ), a cytokine by-product of osteoclast activity, has been identified in biopsy material from stapedectomy [15]. TNF- $\alpha$  has also been identified as a factor responsible for sensorineural hearing loss in experimental animals [14]. Applying the understanding of osteoclastogenesis to the treatment of inner-ear otosclerosis has led to the clinical utilization of the class of drugs called *bisphosphonates*. The bisphosphonate group of drugs specifically targets osteoclasts by reducing production of osteoclasts and accelerating their early cell death [3,16–20]. Before the advent of these newer drugs, fluoride was the only medical treatment for otosclerosis [21–25]. This recent basic science research in the field of osteoclastogenesis leads to a further understanding of the rationale for the use of the bisphosphonate class in the medical treatment of otosclerosis [26].

**Reprint requests:** Kenneth H. Brookler, MD, Neurotologic Associates, PC, 111 East 77th Street, New York, NY 10075. Phone: 212-861-6900; Fax: 212-472-0134; E-mail: khbrooklermd@mac.com

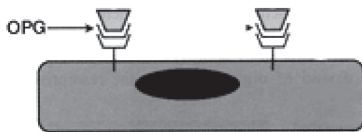
This study was presented in part as a poster presentation to the Politzer Society, Cleveland, OH, October 13–16, 2007.

## CASE REPORTS

Presented here are two cases of patients who underwent stapedectomy. One patient underwent a successful operation but his hearing later deteriorated and, in the second



**Figure 1.** Cartoon of osteoclastogenesis in normal bone. (*M-CSF* = macrophage colony–stimulating hormone; *OPG* = osteoprotegerin; *PTH* = parathyroid hormone; *RANK* = receptor-activator nuclear kappa; *RANKL* = RANK ligand.) (From Steven L. Teitelbaum, Bone resorption by osteoclasts. *Science* 289(5484):1504–1508, 2000. Reprinted with permission from AAAS.)



**Figure 2.** Cartoon of otosclerotic bone with osteoprotegerin (*OPG*) blocking the receptor-activator nuclear kappa receptor.

patient, the procedure was not successful. The medical management using bisphosphonates also is presented.

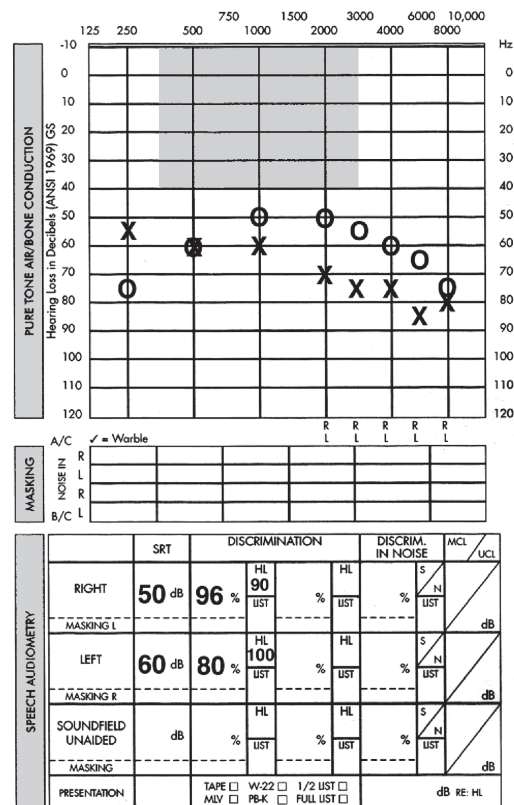
**Patient 1**

This man presented in 1988 at age 47 with a history of progressive hearing loss since age 15. He underwent stapedectomy in the left ear at age 35, with a good result. The right ear was operated on at age 20 and “worked like a charm.” In the last 7 to 8 years, this patient’s hearing has been deteriorating. The patient has a steady hissing sound in both ears, louder on the left. He was placed on sodium fluoride and calcium carbonate (Fig. 3). He was lost to follow-up until 1994, when he returned. He had remained on the sodium fluoride and calcium carbonate in the interim. The hearing showed a drop in the left ear, but the discrimination was similar to that in 1988. He was placed on the early bisphosphonate etidronate along with a supplemental calcium and vitamin D preparation and a fluoride and calcium preparation. He was on this regimen for approximately a year without a change in his hearing. He returned to the sodium fluoride and calcium, and the hearing remained the same, then improved

to 84% discrimination. He returned 2 years later with a drop in discrimination in both ears and in the pure tones in the right ear. The discrimination was 68% in the right ear and 56% in the left ear. When on the sodium fluoride and calcium, hearing improved in the right ear to 84%, whereas in the left ear it dropped to 24% discrimination (Fig. 4).

The patient was placed on alendronate, and the discrimination in the left ear rose to 60% (Fig. 5). He remained on the alendronate, calcium with vitamin D, and sodium fluoride. In January 2001, he was placed on risidronate, 5 mg, to increase to eventually three times weekly. At that visit, the hearing in the left ear had a further air-bone gap and a discrimination score of 56%. It was discovered clinically that the appropriate dose for risidronate was 30 mg twice weekly, on which the patient was placed. The discrimination in the left ear gradually improved so that it reached 76% in the left ear, with a significant air-bone gap (Fig. 6).

The hearing in the right ear has remained at the same level. The patient underwent revision stapedectomy in the left ear in November 2003. The air-bone gap was reduced by 25 dB, allowing him to function better with his hearing aid, with a speech reception threshold of 65 dB rather than 90 dB, while the speech has remained at 72% (Fig. 7).



**Figure 3.** Patient 1. Audiology, June 1988.

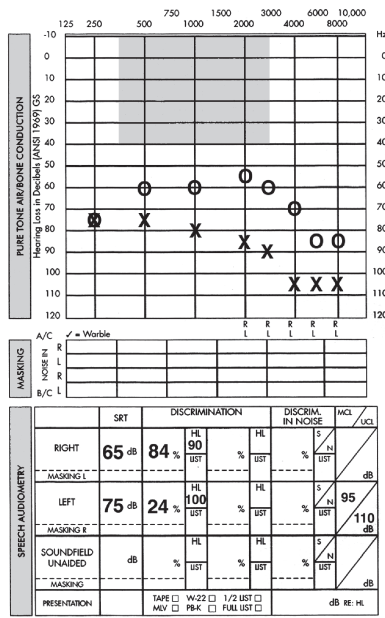


Figure 4. Patient 1. April 1998.

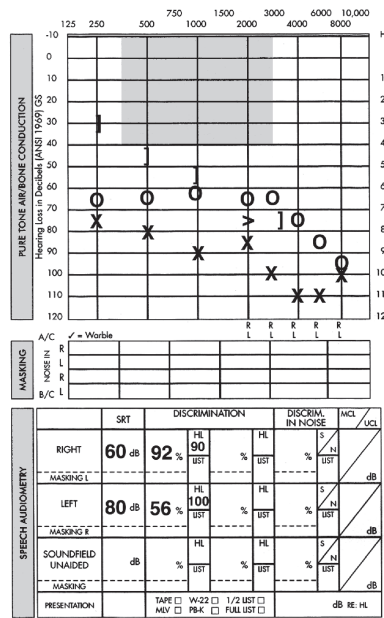


Figure 5. Patient 1. January 2001.

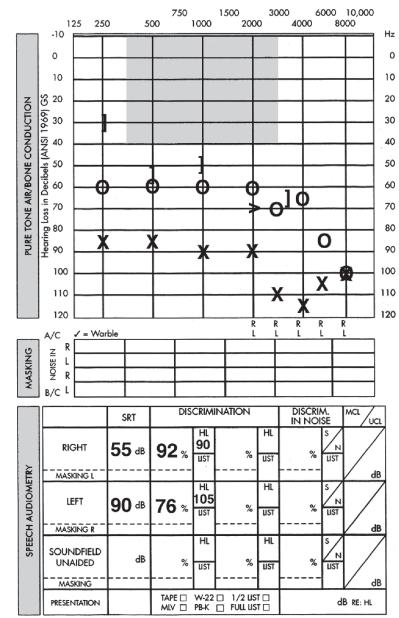


Figure 6. Patient 1. April 2003.

## Patient 2

A 49-year-old man presented with a hearing loss in his right ear for more than 10 years. Nine years before, he had obtained amplification for that ear. With time, the hearing deteriorated further in the right ear, and deterioration began to some degree in the left ear as well. Some 7 years earlier, the patient underwent a stapedectomy in the right ear that resulted in a further decline in threshold

and in discrimination. He subsequently obtained amplification for his left ear. He has some intermittent tinnitus, predominantly in his right ear. The audiological workup revealed a bilateral moderate to severe mixed hearing loss, more pronounced on the right side, with a significant reduction in speech discrimination of 44% (Fig. 8).

The patient was placed on risperidone, 30 mg twice weekly, along with supplemental calcium and vitamin D

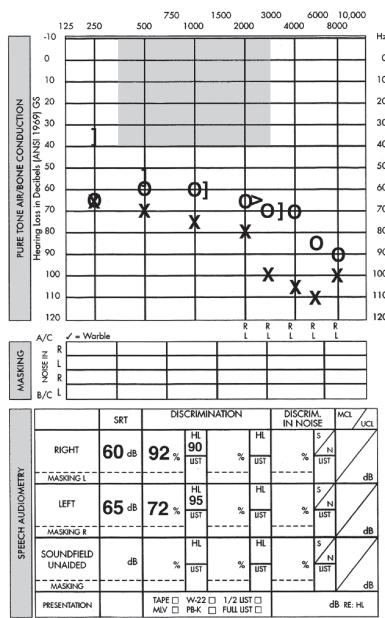


Figure 7. Patient 1. February 2007.

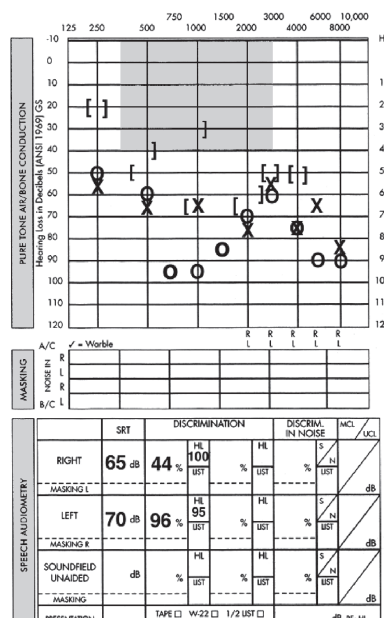


Figure 8. Patient 2. April 2003.

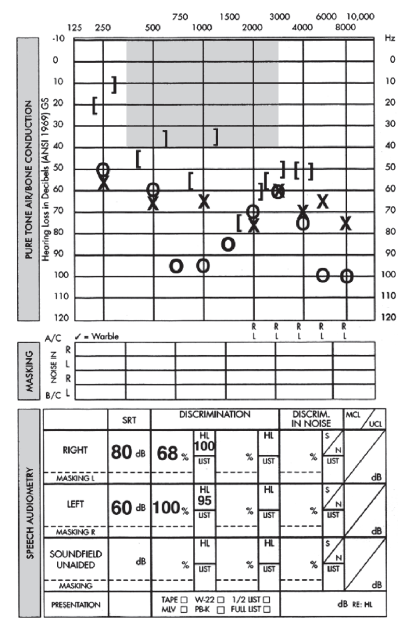


Figure 9. Patient 2. July 2007.

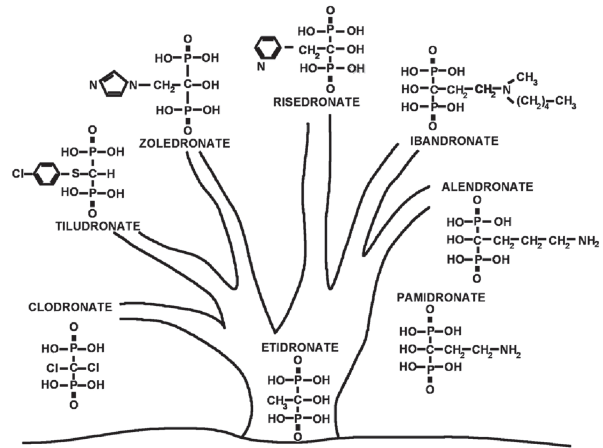
and sodium monofluorophosphate and calcium. His hearing remained nearly level for a year. A year later, etidronate (another bisphosphonate) was added alternately with the risedronate. With subsequent visits, speech discrimination showed progressive improvement to the 68% level, where it has remained. The patient was well aware of his improved ability to communicate with binaural amplification. He especially volunteered that he was able to hear much better in meetings (Fig. 9).

## DISCUSSION

Otosclerosis is a bony dyscrasia of the otic capsule characterized in its active phase by the presence of osteoclasts. The normal otic capsule is devoid of osteoclasts. This normal otic capsule is achieved by a membranous labyrinth that produces OPG, which diffuses through unobstructed channels that have been identified as connecting the perilymph space into the otic capsule [7]. Otosclerosis is triggered by some form of inflammation: The most common inflammation refers to the measles virus. Evidence of both measles RNA and TNF- $\alpha$  have been found in specimens obtained at stapedectomy [11, 13, 14].

RANK ligand is a TNF- $\alpha$  cytokine associated with activation of macrophages to become osteoclasts by attaching at the RANK receptor of the macrophage. Experimental animals that are genetically bred to produce no OPG are shown to develop hearing loss by electrodiagnostic testing and histopathological evidence similar to human otosclerosis [8]. Also possible is that an inflammatory insult to the membranous labyrinth could result in completely or partially reduced production of OPG, also leading to unopposed stimulation of osteoclast production. TNF- $\alpha$  is a cytokine produced by osteoclast breakdown of bone and has been identified as a factor responsible for sensorineural hearing loss in animals with experimentally produced pneumococcal meningitis [15]. Infusing a TNF- $\alpha$  neutralizing agent before inducing the meningitis prevented the meningitis-induced sensorineural hearing loss in these animals. The same channels through which the OPG can diffuse to the otic capsule provide an unobstructed route by which TNF- $\alpha$  can enter the perilymph [7]. TNF- $\alpha$  in the perilymph is presumably toxic to the hair cells producing the symptoms identified.

The bisphosphonates (Fig. 10) are a class of drugs, the first of which was discovered by researchers looking for a new detergent. Etidronate was discovered to have an effect on osteoclasts; it is termed *antiresorptive* in the sense that osteoclasts are targeted. Bisphosphonates are analogs of pyrophosphates that have a common phosphorus-carbon-phosphorus chain, rendering them impervious to breakdown by pyrophosphates. They are



**Figure 10.** Bisphosphonate tree. (Reproduced courtesy of Procter & Gamble.)

resistant to cleavage by alkaline phosphatase. Their chemical structure causes bisphosphonates to be avidly absorbed onto the surface of hydroxyl apatite crystals in bone at sites of active remodeling. They inhibit the activity of osteoclasts when they are engulfed by the osteoclasts during the resorption process.

The effect is to reduce the osteoclast population and slow the production of osteoclasts. In addition, etidronate has an effect of slowing osteoblastic function. Thus, etidronate cannot be used on a continuing basis. With the addition of a nitrogen molecule, the subsequent generation of bisphosphonates more strongly targeted the osteoclasts, sparing the osteoblasts, and could be used on a continuing basis. Clinical experience has revealed risedronate to be the more effective of the oral amine bisphosphonates, but the required effective dose for treating otosclerosis is almost twice the dose used for osteoporosis. This higher dose of bisphosphonates is supported by the findings that the normal otic capsule is devoid of osteoclasts as opposed to the bone subjected to osteoporosis. By chance, the addition of the alternate use of an amine bisphosphonate (risedronate) and a non-amine bisphosphonate (etidronate) appears to exert a maximum effect on inner-ear function.

The bisphosphonate effect is presumably due to decrease of the by-products of bone breakdown that are able to diffuse from the otic capsule through the same channels that allow OPG to gain access from the perilymph. At least one of the products of osteoclast activity is TNF- $\alpha$ . There may be other cytokines produced by osteoclastogenesis that are toxic to the inner ear, presumably the hair cells. By cutting down or eliminating these by-products through the use of bisphosphonates, the effect may be reversed, as was seen in the two case reports presented.

## SUMMARY

The normal otic capsule is devoid of osteoclasts. This state is accomplished by the inner-ear production of OPG. Otosclerosis is an osteoclast-driven disorder of the otic capsule. Stapedectomy may alleviate the conductive component of the otosclerosis, whereas the otic capsular otosclerosis may progress to produce a sensorineural hearing loss.

Osteoclastogenesis (osteoclast formation) has an inflammatory trigger and produces inflammatory by-products of the breakdown of bone. There are channels connecting the otic capsule bone with the perilymphatic fluid space of the inner ear through which OPG diffuses to the otic capsular bone and through which inflammatory by-products from the breakdown of bone can enter the perilymph. These inflammatory by-products are toxic to hair cells.

The bisphosphonate class of drugs targets the osteoclasts by reducing osteoclast production and accelerating osteoclast apoptosis. Reducing osteoclast activity results in less diffusion of the by-products of osteoclast activity to effect hair cell function.

Improved auditory function is evidenced in the two patients described in this article, who had improved bone lines or speech discrimination or both. Bisphosphonates should be considered as a treatment to salvage sensorineural hearing loss occurring after stapedectomy surgery or in association with conductive hearing loss.

## REFERENCES

1. Linthicum FH Jr. Histopathology of otosclerosis. *Otolaryngol Clin North Am* 26:335–352, 1993.
2. Davis GL. Pathology of otosclerosis: A review. *Am J Otolaryngol* 8:273–281, 1987.
3. Chole RA, McKenna M. Pathophysiology of otosclerosis. *Otol Neurotol* 22:249–257, 2001.
4. Frisch T, Sorensen MS, Overgaard S, Bretlau P. Estimation of volume referent bone turnover in the otic capsule after sequential point labeling. *Ann Otol Rhinol Laryngol* 109:33–39, 2000.
5. McKenna M, Gadre AK, Rask-Andersen H. Ultrastructural characterization of otospongiotic lesions in re-embedded celloidin sections. *Acta Otolaryngol* 109:397–405, 1990.
6. Karosi T, Jokay I, Konya J, et al. Activated osteoclasts with CD51/61 expression in otosclerosis. *Laryngoscope* 116:1478–1484, 2006.
7. Zehnder AF, Kristiansen AG, Adams JC, et al. Osteoprotegerin in the inner ear may inhibit bone remodeling in the otic capsule. *Laryngoscope* 115:172–177, 2005.
8. Zehnder AF, Kristiansen AG, Adams JC, et al. Osteoprotegerin knockout mice demonstrate abnormal remodeling of the otic capsule and progressive hearing loss. *Laryngoscope* 116:201–206, 2006.
9. Menger DJ, Tange RA. The aetiology of otosclerosis: A review of the literature. *Clin Otolaryngol* 28:112–120, 2003.
10. Niedermeyer HP, Arnold W. Etiopathogenesis of otosclerosis. *ORL J Otorhinolaryngol Relat Spec* 64:114–119, 2002.
11. Niedermeyer H, Arnold W, Neubert WJ, Hoffer H. Evidence of measles virus RNA in otosclerotic tissue. *ORL J Otorhinolaryngol Relat Spec* 56:130–132, 1994.
12. McKenna MJ, Kristiansen AG. Molecular biology of otosclerosis. *Adv Otorhinolaryngol* 65:68–74, 2007.
13. Karosi T, Jokay I, Konya J, et al. Expression of measles virus receptors in otosclerotic, non-otosclerotic and in normal stapes footplates. *Eur Arch Otorhinolaryngol* 264:607–613, 2007.
14. Aminpour STS, Brodie HA. Role of tumor necrosis factor-alpha in sensorineural hearing loss after bacterial meningitis. *Otol Neurotol* 26:602–609, 2005.
15. Karosi T, Jokay I, Konya J, et al. Detection of osteoprotegerin and TNF-alpha mRNA in ankylotic stapes footplates in connection with measles virus positivity. *Laryngoscope* 116:1427–1433, 2006.
16. Stutzmann JJ, Petrovic AG. Diphosphonates for otospongiosis. *Am J Otol* 6:89–95, 1985.
17. Kennedy DW, Hoffer ME, Holliday M. The effects of etidronate disodium on progressive hearing loss from otosclerosis. *Otolaryngol Head Neck Surg* 109:461–467, 1993.
18. Brookler KH, Tanyeri H. Etidronate for the neurotologic symptoms of otosclerosis: Preliminary study. *Ear Nose Throat J* 76:371–376, 379–381, 1997.
19. Chapurlat RD, Delmas PD. Risedronate: Clinical usage. *Int J Clin Pract* 55:275–278, 2001.
20. Crandall C. Risedronate: A clinical review. *Arch Intern Med* 161:353–360, 2001.
21. Shambaugh GE Jr. Fluoride therapy for otosclerosis. *Arch Otolaryngol Head Neck Surg* 116:1217, 1990.
22. Shambaugh GE Jr. How and when to prescribe sodium fluoride. *Am J Otol* 10:146–147, 1989.
23. Bretlau P, Salomon G, Johnsen NJ. Otospongiosis and sodium fluoride. A clinical double-blind, placebo-controlled study on sodium fluoride treatment in otospongiosis. *Am J Otol* 10:20–22, 1989.
24. Forquer BD, Linthicum FH, Bennett C. Sodium fluoride: Effectiveness of treatment for cochlear otosclerosis. *Am J Otol* 7:121–125, 1986.
25. Causse JR, Causse JB. Clinical studies on fluoride in otospongiosis. *Am J Otol* 6:51–55, 1985.
26. Adachi O, Stankovic KM, Kristiansen AG, et al. Bisphosphonates inhibit bone remodeling in the otic capsule of osteoprotegerin deficient mouse, an animal model of otosclerosis. Poster presentation, Association for Research in Otolaryngology, Phoenix, AZ, 2008.