

The Cervicogenic Otoocular Syndrome: A Suspected Forerunner of Ménière's Disease

Burkhard Franz,¹ Peter Altidis,¹ Bandale Altidis,¹ and Greg Collis-Brown²

¹Tinnitus Research Clinic, Wantirna, and ²Ringwood Manipulative Therapy and Physiotherapy Centre, Ringwood, Victoria, Australia

Abstract: Over a period of 4 years, 420 patients were observed with fullness in the ear, episodic vertigo, fluctuating hearing, and tinnitus. Of them, 182 patients showed normal hearing levels, a mild eustachian tube dysfunction, normal SP/AP ratios, mydriasis on the side of the affected ear, and a functional disorder of the upper cervical spine. These patients responded to conservative management, particularly physiotherapy. Additionally, 51 patients showed normal hearing levels, a mild eustachian tube dysfunction, an elevated SP/AP ratio suggesting endolymphatic hydrops, mydriasis on the side of the affected ear, and a functional disorder of the upper cervical spine. These patients were given a diagnosis of cervicogenic otoocular (COO) syndrome. Within this group, 43 patients did not respond to preceding conservative management, and 3 patients developed Ménière's disease within 12 months. Also within this group, 8 patients responded to physiotherapy only, with return of the SP/AP ratio to normal levels. A total of 187 patients had a sensorineural hearing loss, an elevated SP/AP ratio, mydriasis on the side of the affected ear, a functional disorder of the upper cervical spine; 186 had a mild eustachian tube dysfunction and had diagnosed Ménière's disease. Patients with a COO syndrome invariably responded to the insertion of a middle-ear ventilation tube, with return of the SP/AP ratio to normal levels and relief of symptoms. Patients with Ménière's disease had a mixed response. The COO syndrome is suspected to be a forerunner of Ménière's disease.

Keywords: C1-C2 facet joint disorder; cervicogenic otoocular syndrome; electrocochleography; eustachian tube dysfunction; Ménière's disease

As have many other clinicians we have been observing patients with fullness in the ear, tinnitus, fluctuating hearing, episodic vertigo, and nausea and been surprised to find normal hearing levels but an elevated SP/AP ratio suggesting endolymphatic hydrops. The presence of normal hearing levels inclines toward a diagnosis of vestibular Ménière's disease, but this diagnosis appears untenable if electronystagmography results are unremarkable.

Since the findings of Tumarkin [1], a eustachian tube dysfunction has been suggested to be linked to endolymphatic hydrops. Eustachian tube function tests, however, are not performed routinely, particularly if

tyimpanometry indicates normal middle-ear function in the initial audiological assessment.

What also has been suggested is that a dysfunction of the autonomic nervous system is one of the causes of endolymphatic hydrops [2], but a simple clinical method is not yet available for its assessment in otology.

In addition, a longstanding clinical observation maintains that a functional disorder of the cervical spine frequently is found in patients suffering from Ménière's disease. Although initially regarded as a cause of Ménière's disease, the disorder now is accepted only as an aggravating condition [3].

The hypothetical eustachian tube dysfunction and both dysfunction of the autonomic nervous system and the aggravating condition of a cervical spine disorder were the attraction that inspired us to carry out further investigations in patients who had fullness in the ear, vertigo, and tinnitus but normal audiograms and tympanograms.

We collected data over the last 4 years and com-

Reprint requests: Burkhard Franz, M.D., Tinnitus Research Clinic, 230 Mountain Highway, Wantirna 3152, Victoria, Australia.

Portions of this article were presented at the Prosper Ménière Society Ninth Annual Winter Meeting, March 22-29, 1997, Aspen, CO.

pared these with data from 187 patients with diagnosed Ménière's disease over the same period. A combination of a eustachian tube dysfunction and an elevated SP/AP ratio led to the insertion of a middle-ear ventilation tube, after which electrocochleography was repeated.

METHOD

The eustachian tube function was assessed by three tests using a Madsen impedance bridge. In the velum test, a probe was placed in the vestibulum nasi. The pressure needle of the impedance bridge was observed while patients swallowed with the nose closed. This test enabled us to detect any abnormalities of soft palate movement and showed whether pressure changes in the nasopharynx were monophasic or biphasic.

The Toynbee test was performed with a probe in the external ear canal; through it, positive and negative pressure were applied. Patients were asked to swallow with the nose closed, thus demonstrating the ability to equalize.

The Holmquist test [4] was modified such that negative pressure was created in the middle ear with a Politzer bag. Patients were asked to swallow with one nostril closed while the bag sucked air from the other nostril. This resulted in negative middle-ear pressure, usually between -100 and -200 mm H₂O. Patients then were asked to swallow to demonstrate their ability to equalize.

The function of the autonomic nervous system was assessed by observing patients' pupils. The pupil size was assessed after reacting to light and accommodation. The pupils were examined under Frenzel glasses with the patient facing the observer first. Then a patient's shoulders were turned on a swivel chair in both a clockwise and counterclockwise direction with the patient's head secured in the forward position (Fig. 1). Mydriasis was regarded as positive if the diameter of the pupil changed immediately and the difference of the pupils was at least 1 mm on a grid fixed on the outer glass of the Frenzel glasses.

The function of the cervical spine was assessed by a physiotherapist, with special attention given to the facet joints. The examination consisted of spinal postural assessment, particularly imbalance due to muscle shortening or weakness. The range of active cervical motion was determined, as were the passive physiological and passive accessory joint range.

Electrocochleography using click stimuli was performed with an extratympanic electrode placed on the eardrum, with conduction liquid in the tympanic recess. This arrangement has given excellent morphology of the tracings. A transtympanic electrode was used in those patients who had a hearing loss that generated

Frenzel Glass Test for Assessment of Pupil Size

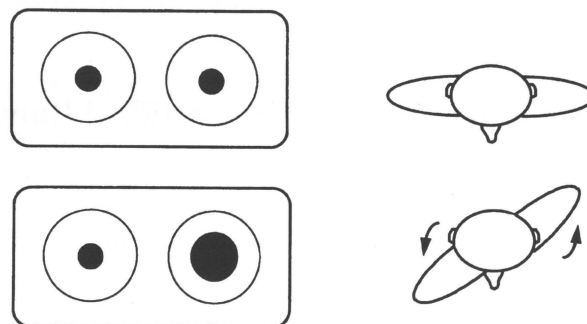


Figure 1. Frenzel glass test for detection of mydriasis. Mydriasis is seen best with a patient's head secured in forward position and turning the shoulder away from the affected ear. An immediate increase of the pupil diameter is regarded as positive.

sufficient clinical suspicion of an endolymphatic hydrops not confirmed with an extratympanic electrode. Use of a transtympanic electrode was necessary in two patients.

In our clinic, the SP/AP ratio is regarded as normal at 13.9 (1.3%). The SP/AP ratio was considered abnormal if it were above 30% in patients with normal hearing levels and above 50% in patients with a sensorineural hearing loss that was equal to or exceeded 50 dB at 4 kHz. The audiological examination was completed with brainstem audiometry and electronystagmography. All patients with diagnosed Ménière's disease underwent a computed tomographic head scan.

RESULTS

Over a period of 4 years since the introduction of eustachian tube function tests and assessment of pupil size, we have examined 420 patients suffering from fullness in the ear, episodic vertigo, fluctuating hearing, and tinnitus (Table 1). The character of the tinnitus ranged from a mild buzzing to clicking and banging noises in the affected ear. The age of the patients ranged from 22 to 69 years; 185 were male and 235 were female. A striking feature in patients' history was that almost all had been to a physiotherapist or chiropractor at one stage in their lives for the treatment of a back or neck problem. Sixty percent had a history of a whiplash injury.

A total of 182 patients had normal hearing levels, a mild eustachian tube dysfunction, and normal SP/AP ratios (average, $16.9 \pm 1.6\%$), but mydriasis and a functional disorder of the upper cervical spine. These patients responded well to conservative management,

Table 1. Comparison of Pre-COO Syndrome, COO Syndrome, and Ménière's Disease

	Pre-COO Syndrome	COO Syndrome	Ménière's Disease
No. of patients	182	51	187
Hearing level	Normal	Normal	Abnormal
Eustachian tube function	Mildly abnormal	Mildly Abnormal	Mildly abnormal
SP/AP ratio	Normal	Elevated	Elevated
	16.9 ± 1.6%	39.4 ± 2.3%	51.3 ± 2.2%
Pupil reaction	Mydriasis	Mydriasis	Mydriasis
Cervical spine	C ₁ -C ₂ disorder	C ₁ -C ₂ disorder	C ₁ -C ₂ disorder

COO = cervicogenic otoocular.

particularly physiotherapy, which brought relief of their symptoms.

Fifty-one patients showed normal hearing levels, a mild eustachian tube dysfunction (ascertained by their failing the Toynbee test and modified Holmquist test), an elevated SP/AP ratio (average $39.4 \pm 2.3\%$), mydriasis, and a functional disorder of the upper cervical spine. These patients had a diagnosis of cervicogenic otoocular (COO) syndrome. Forty-three responded to the insertion of a ventilation tube. The follow-up electrocochleograms showed a return to normal levels (average $15.4 \pm 2.1\%$). Patients experienced relief from their symptoms, particularly fullness in the ear, nausea, vertigo, and the feeling of fluctuating hearing. Although reduced, tinnitus—particularly buzzing in the ear—could not be eliminated in some cases: 10 patients within this group did not respond to preceding conservative management over an average period of 24 months. Three patients rejected the idea of a ventilation tube and developed Ménière's disease within 12 months, and 8 patients within this group responded to physiotherapy only, experiencing return of the SP/AP ratio to normal levels.

A total of 187 patients were given a diagnosis of Ménière's disease. The substantiating findings were a sensorineural hearing loss, an elevated SP/AP ratio (average $51.3 \pm 2.8\%$), mydriasis, and a functional disorder of the upper cervical spine. Within this group, 186 patients failed the Toynbee test and the modified Holmquist test. Of these patients, 46 consented to treatment with a ventilation tube, as a eustachian tube dysfunction could be demonstrated. The success rate was fairly different (Table 2). The symptoms of nine patients im-

proved, consistent with an improvement of the SP/AP ratio, but it remained elevated. Only 31 had relief from their symptoms, with return of the SP/AP ratio to normal levels.

The velum test results were normal in all patients showing a biphasic pressure change in the nasopharynx during swallowing. This outcome suggested a normal mechanism to open the eustachian tube.

DISCUSSION

Since Tumarkin's hypothetical suggestion that endolymphatic hydrops is associated with eustachian tube dysfunction, attempts have been made to treat Ménière's disease with insertion of middle-ear ventilation tubes. A 1969 survey of the effect of ventilation tubes by Lall [5] was not encouraging, nor was a 1977 study by Hall and Brackmann [6]. In 1988, Montandon et al. [7] revived this concept of treatment and, adhering strictly to the criteria of the AAO, had a success rate of 82%. These authors' conclusion was that these patients must have been particularly sensitive to changes of middle-ear pressure. Eustachian tube function, however, was not assessed.

For some time, mydriasis has been regarded as a feature of Ménière's disease, occasionally enabling treating physicians to comment on the state of the condition. In 1980, Uemura et al. [8] concluded that mydriasis is due to paralysis of parasympathetic innervation and most likely is central in origin. Their conclusion was inspired by Williams [2], whose hypothetical treatise maintained that Ménière's disease has a central cause. Uemura et al. were supported by Guidetti and Botti [9] who, in 1990, also concluded that mydriasis associated with endolymphatic hydrops must have a central cause.

We are in agreement with Montandon's observations regarding sensitivity to middle-ear pressure. However, beyond this we suggest that a eustachian tube dysfunction, although not recordable by conventional tympanometry, contributes to the development of an elevated SP/AP ratio. A type A tympanogram does not exclude a eustachian tube dysfunction. As the disorder

Table 2. Response of Ménière's Disease to Insertion of Ventilation Tube (n = 46)

No. of Patients	SP/AP Ratio	Symptoms of vertigo, fullness in the ear
6 (13.1%)	Enlarged $\geq 30\%$	Unchanged
9 (19.6%)	Improved $\geq 30\%$	Improved
31 (67.3%)	Normal $< 30\%$	Resolved

can be demonstrated only by specific tests, it is assumed to be very mild. Return of the SP/AP ratio to normal levels after insertion of a ventilation tube, with subsequent resolution of symptoms, also must be regarded as a strong argument that a eustachian tube dysfunction upsets the SP/AP ratio.

Since 1974, Kumazawa et al. [10] repeatedly have demonstrated eustachian tube dysfunction despite normal tympanograms. Recently, Iwano et al. [11] saw a strong correlation between fullness in the ear and abnormal eustachian tube function using tubotympano-aerodynamography. All patients had normal type A tympanograms.

Our observations agree with Uemura and Guidetti in that mydriasis is part of the Ménière symptom complex. However, we think that a functional disorder of the upper cervical spine plays an important part, at least in patients with normal hearing levels described here. Therefore, we have included that disorder as part of a syndrome.

Our observations disagree with both Uemura et al. and Guidetti and Botti in regard to their conclusion that mydriasis is of central origin. The involvement of a functional disorder of the upper cervical spine would point toward a peripheral cause. This theory is supported by the Frenzel glass test wherein mydriasis is seen on the side of the affected ear. Mydriasis is not always apparent at the start of the examination, while the patient is facing the observer. The disorder is observed mainly during the maneuver of turning the shoulder away from the affected ear (see Fig. 1). During this maneuver, with the head in a fixed position, the cervical sympathetic neurons are activated, leading to this abnormal pupil reaction.

Our view that mydriasis is of peripheral origin and not likely due to paralysis of parasympathetic innervation is supported further by anatomical studies of both Jamieson et al. [12] and Pick [13], showing a close relationship between the upper cervical ganglion and C1-C2 spinal nerves. These authors also demonstrated innervation of C1-C2 facet joints by the anterior branches of the same nerves. In addition, an apparently important note is that today we accept the concept that autonomic ganglia no longer are a relay station distributing nerve signals from central to peripheral. Instead, they integrate nerve activity from different sources and directions.

However, how could activated cervical sympathetic neurons explain the clinical observation of mydriasis and eustachian tube dysfunction at the same time, particularly as stimulation of the sympathetic generally is believed to improve eustachian tube function [14–19]? Over the last 15 years, what has become apparent is that the sympathetic does not use noradrenalin only as a transmitter. A number of new transmitters with diverse

effects have been found, and the list will almost certainly continue to grow.

In 1986, Stone et al. [20] discovered that neuropeptide Y is the transmitter for the dilator pupillae. A recent study by Cervin et al. [21] demonstrated that neuropeptide Y is involved in reducing mucociliary activity of the upper airway mucosa, consistent with eustachian tube dysfunction, and neuropeptide Y being released by preganglionic stimulation of sympathetic neurons. A 1957 anatomical study by Kadanoff and Wassilev [22] demonstrated that the autonomic innervation of the eustachian tube as it stems from the tympanic plexus is a network innervating submucosal glands and is present just under the epithelium. These fibers originate from the upper cervical ganglion that forms the internal carotid plexus, from which the dilator pupillae are innervated as well.

The view that sympathetic innervation of submucosal glands modulates gland secretion by rendering it more viscous appears to render plausible the concept that mydriasis and eustachian tube dysfunction can follow preganglionic sympathetic stimulation (e.g., neuropeptide Y or norepinephrine are the transmitters in the periphery). How a mild eustachian tube dysfunction can upset the balance of the fluid compartments in the inner ear is very speculative at this stage. We are uncertain whether expressing yet another hypothesis is justified. We are uncertain also whether an elevated SP/AP ratio indeed shows endolymphatic hydrops.

Our findings show little change of the SP voltage in patients with COO syndrome. Major changes are observed in the AP voltage, with a significant increase after insertion of a ventilation tube (Fig. 2). These findings might not be surprising, as we have normal hearing levels in the COO syndrome, and existence of a hydrops possibly would require the presence of a hearing loss. What could be the mechanism?

According to Horner [23], a simple shift of perilymph from the scala vestibuli into the scala tympani via the helicotrema would suffice to increase the potassium concentration in the scala tympani and would cause the symptoms of Ménière's disease. This theory is particularly attractive for explaining the COO syndrome, with its increase of the AP voltage after insertion of a ventilation tube. For some time, the potassium concentration in the scala vestibuli has been known to be slightly higher than that in the scala tympani, and potassium is regarded to be toxic to the neurons. This shift of perilymph would be initiated by a mild suction on the round window membrane, as would be expected in a mild eustachian tube dysfunction.

This theory requires the acceptance of a normal flow of fluid from the cerebrospinal fluid to the cochlear aqueduct to perilymph to the round-window membrane to lymph vessels of the middle-ear mucosa and, finally,

Electrocochleograms in COO Syndrome

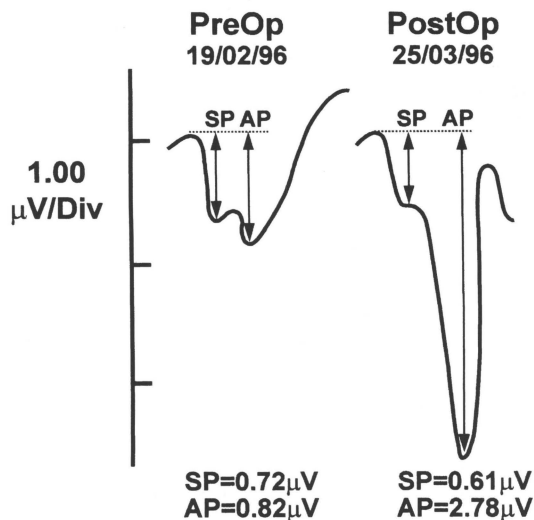


Figure 2. Electrocochleogram of a patient with cervicogenic otoocular syndrome before and after insertion of a middle-ear ventilation tube. The AP voltage increases significantly after insertion of a ventilation tube. The SP voltage remains practically unchanged.

Pat I.D. : I.T. No.7

to the lymph vessels of the neck. Arnold et al. [24], using ink and Thorotrast as a dye, have demonstrated in animals that this pathway and its direction do indeed exist.

CONCLUSION

We have observed a group of patients with specific symptoms belonging to the large family of endolymphatic hydrops. Patients with normal hearing levels and a mild eustachian tube dysfunction responded to the insertion of a middle-ear ventilation tube, which brought relief of their symptoms and return of the SP/AP ratio to normal levels. Patients with hearing losses and diagnosed Ménière's disease exhibited a mixed response.

We believe that the uniqueness of those patients with normal hearing levels permits us to extract this group as an entity. The striking features were normal hearing levels, a mild eustachian tube dysfunction, an elevated SP/AP ratio suggesting endolymphatic hydrops, mydriasis, and a functional disorder of the upper cervical spine. We named this condition the *cervicogenic otoocular syndrome*.

The functional disorder of the upper cervical spine is regarded as a potential threat to the eustachian tube, leading to a very mild dysfunction that upsets the SP/AP ratio of the inner ear. Whether this COO syndrome could be a forerunner of Ménière's disease can be determined only after careful long-term observations. The mixed response of Ménière's disease patients to the insertion of a middle-ear ventilation tube seems to point in that direction.

ACKNOWLEDGMENT

We thank Umberto Rossi, M.D. for his support and constructive comments.

REFERENCES

1. Tumarkin A. Thoughts on the treatment of labyrinthopathy. *J Laryngol Otol* 80:1041–1053, 1966.
2. Williams HL. A review of the literature as to the physiologic dysfunction of Ménière's disease: a new hypothesis as to its fundamental cause. *Laryngoscope* 75:1661–1689, 1965.
3. Meyer Zum Gottesberge A, Stupp H. Ménièresche Krankheit. In Brendes J, Link R, Zoellner F (eds), *HNO-Heilkunde in Praxis und Klinik. Band 6, OHR II*. Stuttgart: Thieme, 1980:38.1–38.27.
4. Holmquist J. Eustachian tube function assessed with tympanometry. *Acta Otolaryngol* 68:501–508, 1969.
5. Lall M. Ménière's disease and the grommet. *J Laryngol Otol* 83:787–791, 1969.
6. Hall CM, Brackmann DE. Eustachian tube blockage and Ménière's disease. *Arch Otolaryngol* 103:355–357, 1977.
7. Montandon P, Guillemin P, Haeusler R. Prevention of vertigo in Ménière's syndrome by means of transtympanic ventilation tubes. *ORL J Otorhinolaryngol Relat Spec* 50:377–381, 1988.
8. Uemura T, Itoh M, Kikuchi N. Autonomic dysfunction on the affected side in Ménière's disease. *Acta Otolaryngol* 89:109–117, 1980.
9. Guidetti G, Botti M. La pupillometrie dans la maladie de Ménière. *Rev Laryngologie* 112:133–136, 1990.
10. Kumazawa T, Honjo I, Honda K. Aerodynamic evaluation of Eustachian tube function. *Eur Arch Otol Rhinol Laryngol* 208:147–156, 1974.

11. Iwano T, Kinoshita T, Hamada E, et al. Sensation of ear fullness caused by eustachian tube dysfunctions. *Auris Nasus Larynx* 18:343-349, 1991.
12. Jamieson RW, Smith DB, Anson BJ. The cervical sympathetic ganglia. *Q Bull NUMS* 591:219-227, 1952.
13. Pick J. *The Autonomic Nervous System. Morphological, Comparative, Clinical and Surgical Aspects* [part 3]. Philadelphia: Lippincott, 1970.
14. Jackson RT. Pharmacological mechanisms in the Eustachian tube. *Ann Otol* 80:313-318, 1971.
15. Malm L, White P. Beta-agonist and surfactant in Eustachian tube function. *Acta Otolaryngol Suppl (Stockh)* 493:133-136, 1992.
16. Sheffield PA, Jackson RT, Davis LJ. Patency changes in dogs Eustachian tube in response to alpha and beta adrenergic drugs. *Ann Otol* 79:117-123, 1970.
17. Svane-Knudsen V, Kruse S, Lildholdt T, Madsen T. Sympathetic influence on the normal Eustachian tube. An experimental study in the rat. *Acta Otolaryngol* 101:263-268, 1986.
18. Uddman R, Alumets J, Densert O, et al. Innervation of the feline Eustachian tube. *Ann Otol* 88:557-561, 1979.
19. Wang H-W, Lin JK, Wang J-Y. Sympathetic innervation of the Eustachian tube in rats. *Eur Arch Otorhinolaryngol* 251:283-286, 1994.
20. Stone Ra, Laties Am, Emson PC. Neuropeptide Y and the ocular innervation of rat, guinea pig, cat and monkey. *Neuroscience* 17:1207-1216, 1986.
21. Cervin A, Lindberg S, Mercke U. Sympathetic nerve stimulation influences mucociliary activity in the rabbit maxillary sinus. *Acta Physiol Scand* 143:405-411, 1991.
22. Kadanoff D, Wassilev W. Über die Innervation der Tuba pharyngotympanica (Tuba auditiva, Eustachii). *Z Mikr Anat Forsch* 63:398-412, 1957.
23. Horner KC. Old theme and new reflections: hearing impairment associated with endolymphatic hydrops. *Hear Res* 52:147-156, 1991.
24. Arnold W, Nitze HR, Ritter R, et al. Qualitative Untersuchungen der Verbindungswege des Subarachnoidalraumes mit dem lymphatischen System des Kopfes und des Halses. *Acta Otolaryngol* 74:411-424, 1972.