

Benign paroxysmal positional vertigo: diagnosis and treatment

Roseli Saraiva Moreira Bittar¹

Raquel Mezzalira²

Paula Lobo Furtado³

Alessandra Ramos Venosa⁴

Andre Luis Lopes Sampaio⁴

Carlos Augusto Costa Pires de Oliveira⁴

Abstract

Benign paroxysmal positional vertigo is a common disorder in Neurotology. This vestibular syndrome is characterized by transient attacks of vertigo, caused by change in head position, and associated with paroxysmal characteristic nystagmus. The symptoms result from movement of the free floating otoconia particles in the endolymph or their attachment to the cupulae of the semicircular canal. The diagnosis is essentially clinical and should be confirmed by performing diagnostic maneuvers. Treatment is based on the identification of the affected semicircular canal and performance of liberatory maneuvers or repositioning of free floating particles of otoliths. The effectiveness varies from 70 to 100%.

Keywords: dizziness, vertigo, vestibular diseases.

¹ University of São Paulo, Brazil. E-mail: roseli.bittar@gmail.com

² University of Campinas, Brazil. E-mail: raquelmezzalira@uol.com.br

³ Hospital de Base of Distrito Federal, Brazil. E-mail: pl.furtado@gmail.com

⁴ University of Brasilia, Brazil. E-mail: alessandravenosa@gmail.com / andremarjy@uol.com.br / cacpoliveira@brturbo.com.br

INTRODUCTION

Benign Paroxysmal Positional Vertigo (BPPV) is one of the most prevalent clinical disorders in common Neurotology practice and accounts for approximately 17% of complaints of vertigo¹. It represents the most important peripheral vestibular impairment along the lifespan^{1,2,3}, although the age at onset is commonly between the fifth and seventh decades of life⁴. However, the time of onset has also been described at childhood^{5,6,7}. It affects from 10.7 to 64% per 100,000 patients a year⁸ (lifetime prevalence of 2.4 percent) [8,9]. Women are more affected than the men in a proportion of 1.5 to 2.21⁹.

Given the noteworthy prevalence of BPPV, its health care and societal impacts are tremendous⁸. It is estimated that it costs approximately US\$2000 to arrive at the diagnosis of BPPV, and that 86 percent of patients suffer some interrupted daily activities and lost days at work because of BPPV⁸.

Positional vertigo is defined as a spinning sensation produced by changes in head position relative to gravity. Benign paroxysmal positional vertigo is defined as a disorder in the inner ear, characterized by repeated episodes of positional vertigo⁸, with typical paroxysmal nystagmus.

BPPV may be diagnosed and treated by multiple clinical disciplines. Despite its significant prevalence, and quality-of-life and economic impacts, considerable practice variations exist in the management of BPPV across disciplines⁸. These variations relate to both diagnostic strategies for BPPV and rates of utilization of various treatment options available for BPPV within and across the various medical specialties and disciplines involved in its management. Delays in the diagnosis and treatment of BPPV have both cost and quality-of-life implications for both patients and their caregivers⁸.

Significant improvements in the diagnosis and treatment of patients with BPPV may lead to significant health care quality improvements as well as medical and societal cost savings. Such improvements may be achievable with the reduction of the inappropriate use of vestibular suppressant medications, decreasing the inappropriate use of unnecessary tests such as radiographic imaging, and by increasing the use of appropriate cost effective therapeutic repositioning maneuvers. In this context, BPPV should be mentioned not only because of the high prevalence, but also because of the relative simplicity of the diagnosis and cost effectiveness of the treatment⁸.

The purpose of this paper is to review the available methods for diagnosis and treatment of BPPV intended for clinicians who are likely to diagnose and manage patients with BPPV, and applies to any setting in which BPPV would be identified, monitored, or managed. To

do this, we performed a non-systematic literature review dealing with BPPV.

CLINICAL PRESENTATION AND PATHOLOGY

The difference of density of the cupulae and labyrinth endolymph leads to the symptoms. Displaced particles from utricle otoliths float around in the endolymph (canalithiasis)¹¹ or adhere to the cupulae (cupulolithiasis)¹² and may change the density relation of the cupulae-endolymph system. The semicircular canals change their gravitational orientation plane while the patients move their head. The debris dislocates and promotes anomalous activation of the ampullar crista and may interfere with the neuronal output index that normally would be expected for that head and canal position. Such sensory conflict leads to balance disorder and nystagmus.

Of the two variants of BPPV, canalithiasis is the most common, and the posterior semicircular canal is the most affected because of its anatomical position (85-95% of cases of BPPV)⁸. The ampulla of the posterior semicircular canal is located in the lower region of the vestibule, both in the supine and standing position. The fragments in suspension inside the labyrinth tend to be deposited in this region, by the action of gravity^{1,13,14,15}. The lateral semicircular canal may be involved in 5 to 15% of patients⁸ and the anterior canal is rarely involved⁸; but there is still the possibility of simultaneous involvement of two canals^{18,19,20}.

Recently, Gacek²¹ proposed a neural theory for BPPV, in which there was degeneration of the saccular ganglion secondary to a latent viral reactivation. Such reinfection could result in the loss of its antagonistic effect on the posterior semicircular canal. This could lead to upward vertical dissociated rotatory nystagmus, of limited duration. Such nystagmus is correlated with activation of the posterior canal.

DIAGNOSIS

The diagnosis of BPPV is essentially clinical. The classic complaint is vertigo in episodes, triggered by changes in the body position or head movements, lasting seconds and ceasing spontaneously. Typically, the vertigo arises in the lateral position of one or both sides, in hyperextension of the head, when standing up or lying down. Usually there are no auditory symptoms^{15,22,23}. Some other symptoms could be associated and often persist after the interruption of the episode, such as nausea, imbalance, or postural instability^{1,15}. Besides the clinical history, the diagnosis of BPPV takes into account the type, direction and duration of nystagmus provoked by maneuvers that provide clues for identifying the

affected canal and the pathophysiological mechanism involved (whether canalithiasis or cupulolithiasis).

Identifying the affected canal includes observation of the position that triggers the dizziness and the resulting type of nystagmus. Each of the semicircular canals is directly connected to a pair of extrinsic muscles in the eye, having an excitatory and inhibitory influence, which determines the movement of the eyeball in the same plane as the canal²⁴ (Table 1).

Table 1. Connections between semicircular canals and eye muscles.

SEMICIRCULAR CANAL	EXCITATION	INHIBITION
HORIZONTAL	IPSILATERAL MEDIAL RECTUS	CONTRALATERAL MEDIAL RECTUS
	CONTRALATERAL LATERAL RECTUS	IPSILATERAL LATERAL RECTUS
POSTERIOR	IPSILATERAL SUPERIOR OBLIQUE	IPSILATERAL INFERIOR OBLIQUE
	CONTRALATERAL INFERIOR RECTUS	CONTRALATERAL SUPERIOR RECTUS
ANTERIOR	IPSILATERAL SUPERIOR RECTUS	IPSILATERAL INFERIOR RECTUS
	CONTRALATERAL INFERIOR OBLIQUE	CONTRALATERAL SUPERIOR OBLIQUE

When the patient gets in the position that triggers the dizziness, eye movement is observed resulting from the contraction of muscles related to the affected canal (slow component), followed by subsequent rapid correction in the opposite direction (fast component). This biphasic movement, called nystagmus, is a standard direction that is known as being the same as the fast component.

In the vertical canals, there are excitatory connections to the ipsilateral superior oblique and contralateral inferior rectus to the posterior canal; ipsilateral superior rectus and contralateral inferior oblique to the superior canal, so that the arising movements are always rotational, but the nystagmus is vertical upward in the posterior canal and vertically downward in the superior canal²³.

The characterization of the nystagmus, allows the identification of the canal involved as well as the mechanism involved, and it is essential to choose the repositioning procedure. In Table 2, we can observe the main features of involvement of different semicircular canals.

DIAGNOSTIC MANEUVERS

1. Dix-Hallpike Maneuver

The Dix-Hallpike maneuver is considered the gold standard tool for the diagnosis of BPPV of posterior canal⁸.

The Dix-Hallpike maneuver is performed by the clinician moving the patient through a set of specified head-positioning maneuvers to elicit the expected characteristic nystagmus of posterior canal BPPV (Figure 1). Before beginning the maneuver, the clinician should counsel the patient regarding the upcoming movements and warn that they may provoke a sudden onset of intense subjective vertigo, possibly with nausea, which will subside within 60 seconds. Because the patient is going to be placed in the supine position relatively quickly with the head position slightly below the body, the patient should be oriented so that, in the supine position, the head can “hang” with support off the posterior edge of the examination table by about 20 degrees. The examiner should ensure that he can support the patient’s head and guide the patient through the maneuver safely and securely, without the examiner losing support or balance himself⁹.

Table 2. Variants of BPPV in accordance to the characteristics of positioning nystagmus.

	PSC-Can CANALITHIASIS or CUPULOLITHIASIS	SSC-Can CANALITHIASIS or CUPULOLITHIASIS	LSC-Can CANALITHIASIS	LSC-Can CUPULOLITHIASIS
DURATION	PAROXYSMAL	PAROXYSMAL	PAROXYSMAL	PERSISTENT
STIMULATED MUSCLE	IPSILATERAL SO CONTRALATERAL IR	IPSILATERAL IO CONTRALATERAL SR	IPSILATERAL MR CONTRALATERAL LR	IPSILATERAL LR CONTRALATERAL MR
FAST COMPONENT DIRECTION	RIGHT VERTICAL UPWARD ROTATIONAL COUNTER-CLOCKWISE	VERTICAL DOWNWARD ROTATIONAL COUNTER-CLOCKWISE	HORIZONTAL GEOTROPIC TOWARD RIGHT	HORIZONTAL APOGEOTROPIC TO- WARD LEFT
	LEFT VERTICAL UPWARD ROTATIONAL CLOCKWISE	VERTICAL DOWNWARD ROTATIONAL CLOCKWISE	HORIZONTAL GEOTROPIC TOWARD LEFT	HORIZONTAL APOGEOTROPIC TO- WARD RIGHT
NYSTAGMUS LATENCY	YES	YES	YES	NO

PSC-Can posterior semicircular canal; SSC-Can: superior semicircular canal; LSC-Can: lateral semicircular canal. SO – superior oblique; IR – inferior rectus; IO – inferior oblique; SR – superior rectus; MR – medial rectus; LR – lateral rectus.

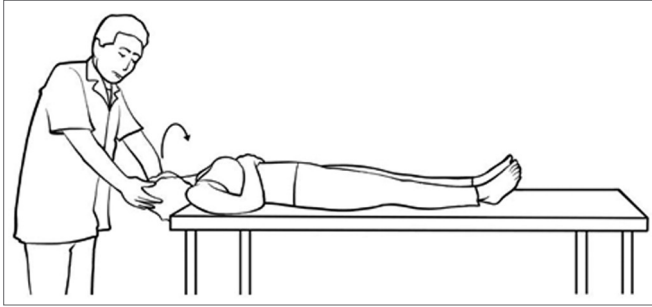


Figure 1. Position of the Dix Hallpike test to evaluate the left posterior semicircular canal.

The maneuver begins with the patient in the upright seated position with the examiner standing at the patient's side. We describe the maneuver to test the left ear as the source of the posterior canal BPPV. The examiner rotates the patient's head 45 degrees to the left and, with manual support, maintains the 45-degree head turn to the left during the next part of the maneuver⁸. Next, the examiner fairly quickly moves the patient (who is instructed to keep the eyes open) from the seated to the supine left-ear down position and then extends the patient's neck slightly (approximately 20 degrees below the horizontal plane) so that the patient's chin is pointed slightly upward, with the head hanging off the edge of the examining table and supported by the examiner. The examiner observes the patient's eyes for the latency, duration, and direction of the nystagmus. Again, the provoked nystagmus in posterior canal BPPV is classically described as a mixed torsional and vertical movement with the upper pole of the eye beating toward the dependent ear. The patient should also be queried as to the presence of subjective vertigo⁸.

After resolution of the subjective vertigo and the nystagmus, if present, the patient may be slowly returned to the upright position. During the return to the upright position, a reversal of the nystagmus may be observed and should be allowed to resolve⁸. The Dix-Hallpike maneuver should then be repeated for the right side, with the right ear arriving at the dependent position. Again, the examiner should inquire about subjective vertigo and identify objective nystagmus, when present. The examination of the right side completes the test⁸.

The particles present inside the semicircular canal undergo the effects of gravity and are shifted downward, and after a short latency, the liberating force created on the ampullar crista triggers the vertigo and nystagmus (Figure 2).

In the case of the superior semicircular canal, a torsional downbeating nystagmus is exhibited. The direction of the torsional component of the positioning nystagmus indicates which ear is the origin of nystagmus. If the upper pole of the eye beats away from the ground

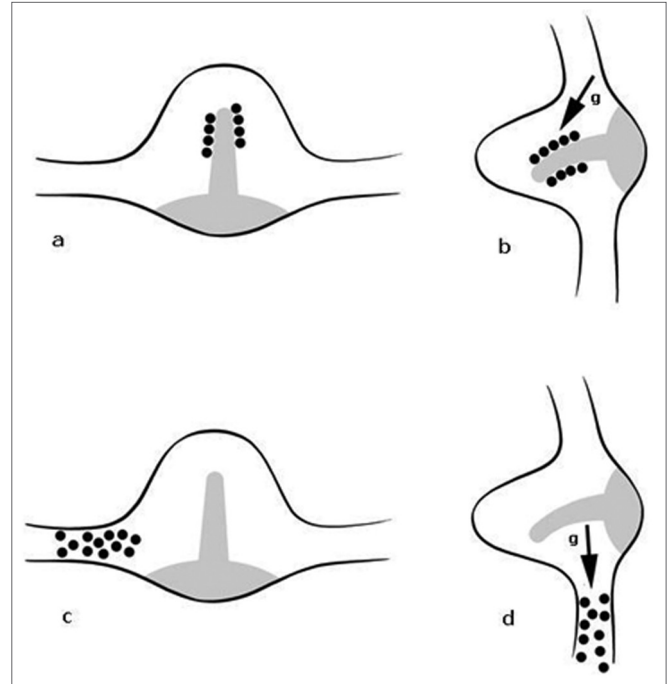


Figure 2. Mechanism of displacement of the debris from the dome of the canal at rest and under the action of gravity (g), indicated by the arrow. (a) and (b) – cupulolithiasis; (c) and (d) – canalolithiasis.

toward the uppermost ear, then it originates from the anterior canal of the uppermost ear. If it beats toward the ground then it originates from the undermost ear.

2. Supine Head Roll Test

If the patient has a history compatible with BPPV and the Dix-Hallpike test is negative, the clinician should perform a supine roll test to assess for lateral semicircular canal BPPV⁸.

Lateral canal BPPV (also called horizontal canal BPPV) is the second most common type of BPPV. Because this type of BPPV has received considerably less attention in the literature, clinicians may be relatively unaware of its existence and the appropriate diagnostic maneuvers for lateral canal BPPV⁸. Patients with a history compatible with BPPV (ie, repeated episodes of vertigo produced by changes in head position relative to gravity) who do not meet diagnostic criteria for posterior canal BPPV should be investigated for lateral canal BPPV.

In many instances, the presenting symptoms of lateral canal BPPV are indistinguishable from posterior canal BPPV. The supine roll test is performed by initially positioning the patient supine with the head in neutral position, followed by quickly rotating the head 90 degrees to one side with the clinician observing the patient's eyes for nystagmus. After the nystagmus subsides (or if no nystagmus is elicited), the head is then returned to the straight face-up supine position. After any additional elicited nystagmus has subsided, the head is then quickly

turned 90 degrees to the opposite side, and the eyes are once again observed for nystagmus. Two potential nystagmus findings may occur with this maneuver, reflecting two types of lateral canal⁸.

The direction of nystagmus is defined by the form of the disease. In canalithiasis, the movement of the head toward the affected ear promotes the displacement of free particles in the direction of the ampulla, triggering a horizontal nystagmus whose fast component will be toward the tested ear, so geotropic (towards the ground). When the head is rotated to the healthy side, the particles displace and lead to a current moving in the opposite direction from the ampulla (also generating geotropic nystagmus), and the stimulation is less intense than that observed on the affected side. Thus, the resulting eye movement is always stronger when the affected ear is placed downward²³. In cupulolithiasis, the fragments are adhered to the cupulae of the affected semicircular canal, which make them heavier than the endolymph. When the head is rotated to one side, the action of gravity on the ampullar crista moves the debris into the opposite direction and it is possible to observe the nystagmus that is in the opposite direction from the tested ear (apogeotropic type)^{24,25}.

The geotropic form is predominant⁸. The mechanisms that initiate geotropic and apogeotropic eye movements can be seen in Figure 3.

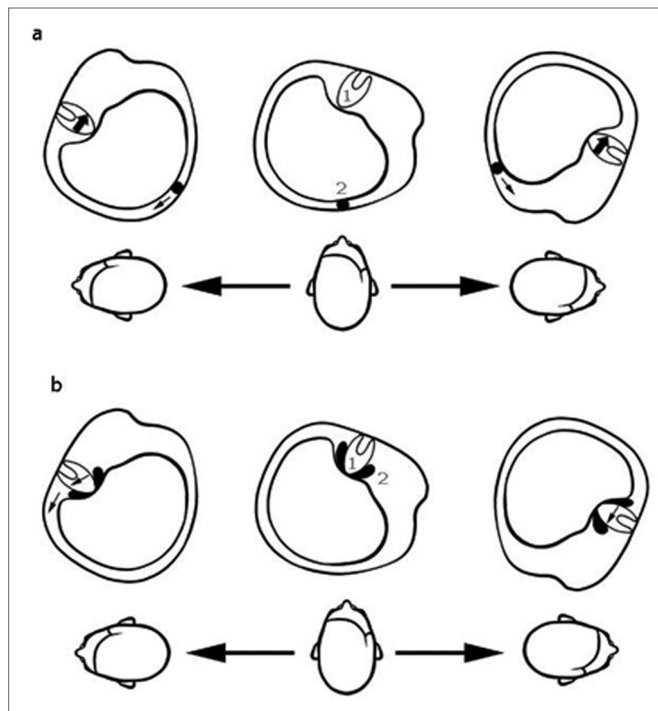


Figure 3. We can observe the mechanism of displacement of the ampullar crista that is responsible for the origin of geotropic nystagmus in canalithiasis(a), or for apogeotropic nystagmus in cupulolithiasis (b). 1 - ampullar crista, 2 - fragments of otoliths. The arrows indicate the direction of displacement of the cupulae by gravity with the lateralization movement of the head.

Due to an adaptation of the central nervous system^{8,26} or to the reversion of the direction of movement of the debris by the gravitational action²⁶, it is not unusual that nystagmus spontaneously changes the direction without the head turning to the opposite side^{8,26}. De la Meilleure et al.²⁶ reported the inversion of the horizontal nystagmus, in electronystagmography, in 75% of patients with BPPV of the lateral canal, always on the affected side. Lee and colleagues²⁷ described the spontaneous reversal of nystagmus bilaterally, and the primary phase of nystagmus was shorter and with greater velocity of the slow-phase.

ETIOLOGICAL DIAGNOSIS

BPPV is idiopathic or secondary to other clinical conditions, i.e.: head trauma (7 to 17%), vestibular neuritis (up to 15%), Meniere's disease (0.5 to 31%)^{28,29,30}. Boaglio et al.³¹ reported the BPPV in 68% of patients with Meniere's disease. Other possible causes are ovarian hormonal dysfunction, hyperlipidemia, hypoglycemia or hyperglycemia, hyperinsulinemia, migraine, cervical trauma, otological surgery, sedentary and prolonged bed rest^{2,15,32,33,34}.

ADDITIONAL EXAMS

Additional exams are essential to clarify the trigger and associated features of BPPV^{1,15, 23,35}.

1. Radiographic imaging

Imaging is not useful in the routine diagnosis of BPPV because there are no radiological findings characteristic of or diagnostic for BPPV⁸. Further radiographic imaging may play a role in diagnosis if the clinical presentation is felt to be atypical, if the diagnostic maneuvers are unusual, or if additional symptoms aside from those attributable to BPPV are present, suggesting an accompanying modifying central nervous system or otological disorders⁸.

2. Vestibular testing

Electronystagmography has limited utility in the vertical canal BPPV diagnosis, since the torsional component of nystagmus cannot be registered by conventional techniques. On the other hand in horizontal semicircular canal BPPV diagnosis, the nystagmus is present in the positional testing²³.

The vestibular test battery is able to evidence associated abnormalities, relatively common in BPPV, but nonspecific^{10,36}, i.e.: vestibular hypofunction (35% of the BPPV cases). Unilateral vestibular hypofunction could or not be associated to the affected side. Thus, it is not a prognostic feature of recurrence²⁰. It has been proposed by Korres²² that the unilateral vestibular hypofunction is

more common in cases secondary to head trauma or viral infection.

3. Audiometric Testing

Audiometry is not required for diagnosing BPPV, however it may offer additional information in cases where the clinical diagnosis of vertigo is unclear⁸.

DIFFERENTIAL DIAGNOSIS

Positional vertigo and nystagmus could be associated with disorders in the central nervous system, i.e.: neurovascular compression of cranial nerve VIII, vestibular schwannoma, Arnold-Chiari malformation and a variety of cerebellar disorders⁸.

TREATMENT

The treatment of BPPV is based on the performance of liberatory maneuvers or canalith repositioning procedures, with the aim of returning the displaced particles to their original location: utricular macula. These are non-invasive procedures that have been found to be long term effective for BPPV^{2,14}.

A standard protocol, that is described in Table 3, is used in our service, considering the better results for each maneuver indicated for each BPPV variant. There are others maneuvers described in the literature, indicated to each BPPV variant. Successful treatment depends mainly on the choice of the most appropriate maneuver for the case.

Table 3. Maneuver according each BPPV variant[1,14,23].

VARIANT BPPV	MANEUVER
LEFT PSC-Can CANALITHIASIS	Epley beginning on the left
LEFT PSC-Can CUPULOLITHIASIS	Semont toward the left Head turned to the right
RIGHT PSC-Can CANALITHIASIS	Epley beginning on the right
RIGHT PSC-Can CUPULOLITHIASIS	Semont toward the right Head turned to the left
LEFT SSC-Can CANALITHIASIS	Epley beginning on the left
LEFT SSC-Can CUPULOLITHIASIS	Semont toward the left Head turned to the left
RIGHT SSC-Can CANALITHIASIS	Epley beginning on the right
RIGHT SSC-Can CUPULOLITHIASIS	Semont toward the right Head turned toward right
LEFT LSC-Can CANALITHIASIS OR CUPULOLITHIASIS	Lempert toward the right ear
RIGHT CANALITHIASIS OR CUPULOLITHIASIS	Lempert toward the left ear

PSC-Can: posterior semicircular canal; SSC-Can: superior semicircular canal; LSC-Can: lateral semicircular canal.

Some patients manifest severe symptoms with dizziness, nausea, sweating and vomiting while undergoing diagnostic or therapeutic maneuvers. In these cases, vestibular suppressant medications are recommended as adjuncts not only to relieve the vertigo after maneuver but also to control the clinical symptoms until the procedure can be repeated⁴. Therapeutic categories include meclizine, dimenhydrinate, clonazepam, diazepam. Dosage may vary in function of the intensity of symptoms. Some authors prefer to wait for the natural course towards a spontaneous relief, considering BPPV a self-limited condition. Clinical remission can occur in three to four weeks^{37,38}.

1. Epley Maneuver

The Epley maneuver³⁹ is the most frequently performed repositioning maneuver of the vertical canal. The patient is placed in the upright position with the head turned 45 degrees to left when the left ear is affected. The patient is rapidly laid back in a supine head-hanging position, which is maintained for a period of 1 to 2 minutes. Next, the head is turned 90 degrees, to the right (usually necessitating the patient's body to move from supine position to the lateral decubitus position). Thus, the patient's head is nearly in the facedown position. This position is held for 30 to 60 seconds. Then the patient is asked to rest the chin on the shoulder and sit up slowly, completing the maneuver⁸ (Figure 4). The head must stay in that position for some moments, before it returns to the normal position^{1,4,23,40}. Figure 5 demonstrates the procedure.

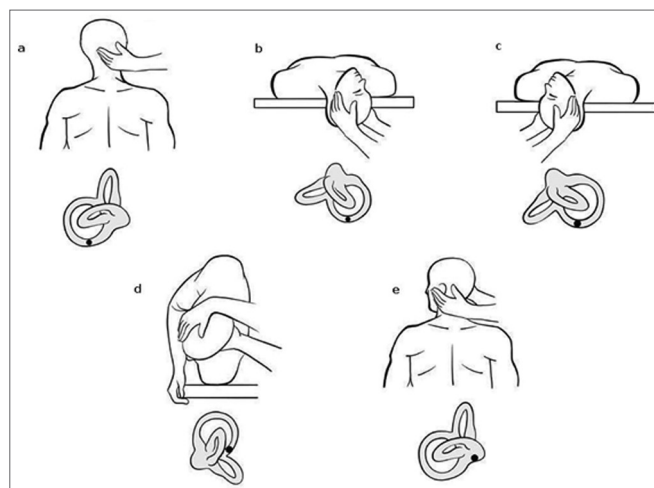


Figure 4. Epley Maneuver for right-sided posterior semicircular canal BPPV.

According to the clinical practice guideline⁸, based on the review of the literature, it was not possible to determine the optimal number of cycles for the repositioning maneuvers.

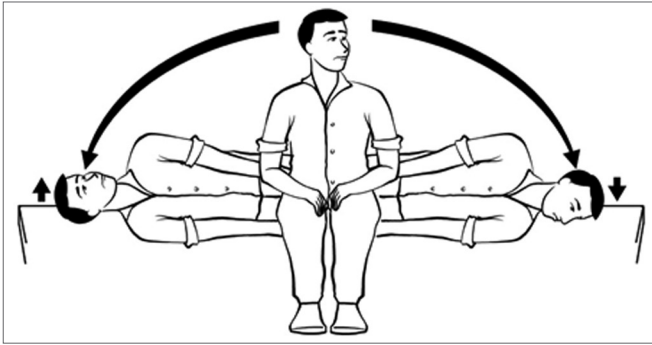


Figure 5. Semont Maneuver for treatment of right-sided posterior semicircular canal cupulolithiasis.

2. Semont Maneuver (liberatory maneuver)

The maneuver described by Semont⁴¹ is indicated for the treatment of posterior canal cupulolithiasis. If the posterior canal is affected, the patient is seated in the upright position; then the patient's head is turned 45 degrees toward the unaffected side, and then is rapidly moved to the side-lying position. Nystagmus and vertigo may be observed. This position is held for 1 to 3 minutes. The patient is rapidly moved to the opposite side-lying position without pausing in the sitting position and without changing the head position relative to the shoulder. Gradually the patient resumes the upright sitting position⁸. If the superior semicircular canal is affected, the movement is performed in the direction opposite to the procedure for posterior semicircular canal^{4,15,23,40}. Figure 6 demonstrates the Semont Maneuver for treatment of right-sided posterior semicircular canal cupulolithiasis.

3. Lempert Maneuver

Lempert⁴² described a maneuver (Barbecue Maneuver or Roll Maneuver) which is the most commonly employed maneuver for the treatment of lateral canal BPPV. This maneuver involves rolling the patient 360 degrees in a series of steps to effect particle repositioning⁸. The patient is in supine position; the patient's head is turned 90 degrees slowly toward the unaffected side. The head is held in this position, and the body is turned to lateral decubitus. Then, the head is turned to the facedown position and the body is moved to the ventral decubitus. Later the patient's head is turned 90 degrees, and the body is placed on lateral decubitus. Gradually, the patient resumes the supine position. Each step is maintained for 15 seconds – for slow migration of the particles, in response to gravity. To complete the maneuver, the patient is brought into the upright sitting position with head bowed down at 30 degrees^{23,43,44}. The maneuver sequence is represented in Figure 7.

4. Forced prolonged position

Forced prolonged position is another treatment

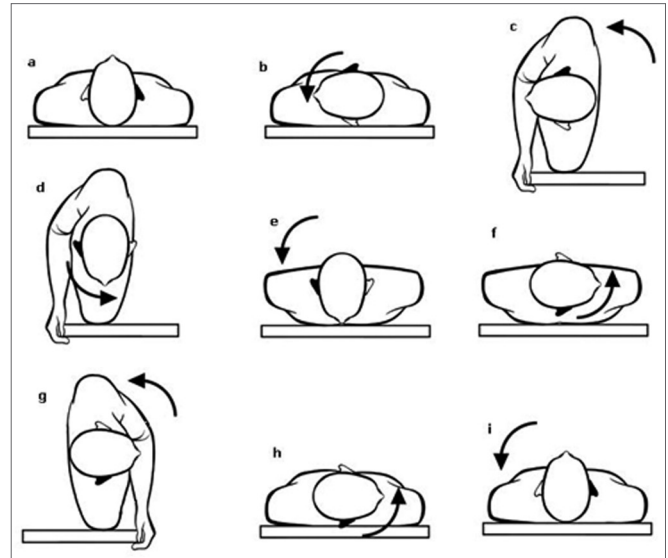


Figure 6. Demonstration of Lempert Maneuver sequence – treatment of lateral semicircular canal BPPV (right ear in black).

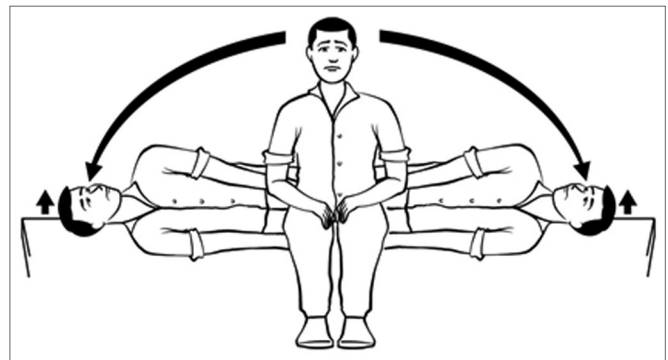


Figure 7. Brandt-Daroff exercises for home self-administration treatment.

maneuver, described by Vannuchi⁴⁴, for the treatment of lateral canal BPPV. The strategy consists of maintaining the forced lateral decubitus, with affected ear in the undermost position for 12 hours^{23,25}.

5. Brandt-Daroff exercises

The Brandt-Daroff exercises were developed for home self-administration, as an additional therapy for patients who have been symptomatic, even after Epley or Semont maneuver⁴⁰. Some authors indicate them one week before the therapeutic maneuver, aiming to improve the patient's tolerability¹⁴. The Brandt-Daroff exercises (Figure 8) are positioning exercises that, theoretically, promote habituation⁴.

The involvement of more than one semicircular canal is not unusual. In these cases, the repositioning maneuver will be applied in steps. The treatment of each affected semicircular canal will be performed, in protocols according to the observed ocular movements and the

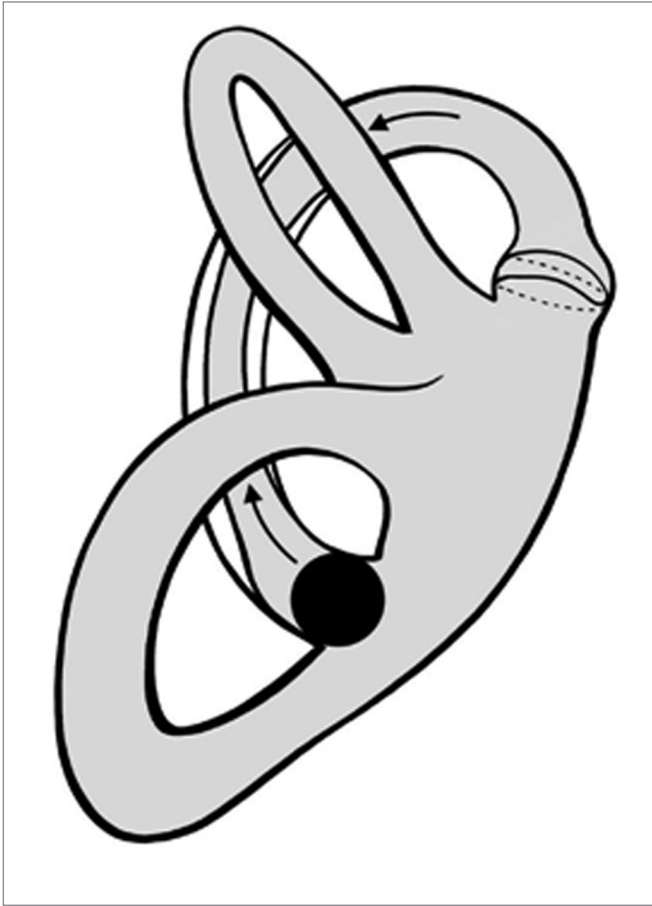


Figure 8. Canalith Jam - negative pressure in the semicircular canal cupulae. Dotted line evidences the original position cupulae.

correct identification of each affected semicircular canal.

Many patients complain of imbalance during and between vertigo attacks, as observed by Çelebisoy⁴⁵. This observation led to the investigation of postural balance in patients with lateral and posterior semicircular canal BPPV. Patients with posterior BPPV had impaired static balance ability when visual and proprioceptive inputs were inadequate as described by Çelebisoy⁴⁵, Di Girolamo⁴⁶.

The otolithic dysfunction induced by unequal loads of the macular beds has been considered as the underlying mechanism⁴⁶. Other possibilities are the persistency of small amounts of residual debris in the canal, paresis of the ampullar receptors or the vestibular re-adaptation after peripheral disorder⁴⁵.

COMPLICATIONS OF MANEUVERS

The repositioning maneuvers are associated to mild and self-limited adverse effects in about 12 percent of the treated patients⁸. The most commonly encountered complications include nausea and vomiting. The

conversion to lateral canal BPPV (so called canal switch) and Canalith Jam are unusual conditions, however when present must be promptly diagnosed and treated⁴⁷.

1. Canal switch

During the course of repositioning maneuvers of vertical canals, the displaced particles could migrate into the lateral canal, in 6 to 7 % of the cases⁸. In these cases, the torsional nystagmus becomes horizontal and geotropic^{43,48,49}. The treatment is Lempert Maneuver⁴⁷.

2. Canalith Jam

During the repositioning maneuvers, some patients develop severe, persistent vertigo, nausea, vomiting and nystagmus, which has the same features observed in the diagnostic maneuvers. This phenomenon could result from a jamming of the otolithic debris (named jam) when migrating from a wider to narrower segment, such as from the ampulla to the canal or at the bifurcation of the common crus⁵⁰. In the Epley Maneuver, it happens when the head of the patient is turned to facedown position (Figure 5 – position c and d). The jam generates a constant counter-attraction force in the cupulae, as result from negative pressure. The jam pressure induces cupulae displacement and consequent depolarization (vertical canals) or hyperpolarization (lateral canals). The nystagmus does not change with head position movement.

The treatment consists of performance of the reverse maneuver, to aim to eliminate the blockade. Thus, the crista returns to the rest position^{13,47,48}. If the patient develops important symptoms, vestibular suppressant medications may be considered to help in a later repositioning. The canalith jam incidence, during repositioning maneuvers, is about 8%².

By virtue of possible complications during the repositioning procedures, it is not a proper conduct to guide the patient self-treatment at home, without a physician.

POSTTREATMENT RESTRICTIONS

After repositioning procedures, it is important to keep the patient in sitting position, for 10 minutes, to avoid falls⁵¹. The use of a cervical collar, positional avoidance, or other restrictions are not necessary^{52,53,54}. Vestibular suppressant medications could be useful.

Epley³⁹, in his original paper, described the application of a bone conduction vibrator associated to repositioning maneuver, in order to release some adhered particles in the ampullar crista. However, studies found no benefit in the BPPV treatment, since it does not modify the results of repositioning or liberatory maneuvers^{2,55,56,57}.

MANEUVERS PROGNOSIS

The effectiveness of repositioning and liberatory maneuvers varies from 70% to 100%^{14,15,23,48}. The successful treatment is based on the identification of the affected semicircular canal, the distinction between cupulolithiasis and canalithiasis, the right choice of the most indicated maneuver². The symptoms recurrence, after complete remission, varies from 4 to 32%^{33,39,47}. Possible explanations include some comorbidities and patient limitations during the maneuvers (for example: limited cervical range of motion or vascular failure)¹⁴. Generally, a new procedure leads to symptoms relief⁴. In long-term, recurrence after Lempert and Epley maneuvers, in ten years, is about 18%².

It is important to be careful when performing diagnostic, repositioning and liberatory maneuvers in obese patients, with limited cervical range of motion or with unstable heart failure or carotid stenosis^{8,25,58}.

Some authors believe in natural course of BPPV toward spontaneous relief^{48,59,60,61,62}, which is possible in up to 89% of the patients in the first month, with subsequent recurrence in up to 33%, in three years^{37,38}. The spontaneous resolution is faster in the lateral semicircular canal BPPV than in posterior canal because the former spatial and anatomic orientation facilitates the return of the particles to their original place^{63,64}. Therefore, it is possible to propose to the patient to wait the spontaneous resolution, in cases where the maneuver can't be indicated.

BPPV MONITORING

Thirty to 50 % of the patients have vestibular system dysfunction associated with initially treated BPPV, which can be demonstrated by caloric testing abnormalities. Therefore, even if symptoms are typical of BPPV, the diagnostic maneuver has been positive, the repositioning maneuver has been successful, it is important that complete neurotological evaluation is obtained to rule out other vestibular disorders.

In recurrence or failed cases, it may be consider that central disorders are possible causes of vertigo, particularly those associated to cerebellar vermis or brain stem, i.e.: cerebellar degeneration, Arnold-Chiari malformation and fourth ventricle roof lesions⁶⁵. These abnormalities should present nystagmus with features [23,66] listed in Table 4.

CONCLUSION

BPPV is a common syndrome in clinical practice. For the therapeutic maneuvers, correct diagnosis of the BPPV variant and affected semicircular canal is necessary. These maneuvers provide a quick relief for patients.

Table 4. Features of positional nystagmus with central origin.

NYSTAGMUS WITHOUT LATENCY
EXTENDED DURATION, GENERALLY MORE THAN 60 SECONDS
DOWN OR UPBEATING
NYSTAGMUS NOT ASSOCIATED TO STIMULATED CANAL
NYSTAGMUS WITHOUT FATIGABILITY
NYSTAGMUS WITH INCREASED AND DECREASED INTENSITY
CHANGE OF DIRECTION
NAUSEA AND VOMITNG NOT ASSOCIATED TO NYSTAGMUS AND VERTIGO INTENSITY
CEREBELLAR AND OCULOMOTOR FINDINGS

A complete neurotological evaluation is important to rule out concomitant disorders. Central etiologies must be investigated when atypical nystagmus is found and therapeutic maneuvers are unsuccessfully.

BIBLIOGRAFY

1. Parnes LS, Agrawal SK, Atlas J. Diagnosis and management of benign paroxysmal positional vertigo (BPPV). *CMAJ* 2003;169(7):681-93.
2. Prokopakis EP, Chimona T, Tsagournikas M, Christodoulou P, Hirsch BE, Lachanas VA, et al. Benign paroxysmal positional vertigo: 10 year experience in treating 592 patients with canalith repositioning procedure. *Laryngoscope* 2005;115:1667-71.
3. Choung Y, Shin YR, Kahng H, Park Keehyum, Choi SJ. 'Bow and lean test' to determine the affected ear of horizontal canal benign paroxysmal positional vertigo. *Laryngoscope* 2006;116:1776-81.
4. Koelliker P, Summers R, Hawkins B. Benign paroxysmal positional vertigo: diagnosis and treatment in the emergency department. A review of the literature and discussion of canalith-repositioning maneuvers. *Ann Emerg Med* 2001;37(4):392-8.
5. Mizukoshi K, Watanabe Y, Shojaku H, Okubo J, Watanabe I. Epidemiological studies on benign paroxysmal positional vertigo in Japan. *Acta Otolaryngol Suppl* 1988;447:67-72.
6. Marcelli V, Piazza F, Pisani F, Marciano E. Neuro-otological features of benign paroxysmal vertigo and benign paroxysmal positioning vertigo in children: a follow-up study. *Brain Dev.* 2006;28(2):80-4.
7. Bachor E, Wright CG, Karmody CS. The incidence and distribution of copular deposits in the pediatric vestibular labyrinth. *Laryngoscope* 2002;112:147-51.
8. Bhattacharayya N, Baugh RF, Orvidas L, Barrs D, Bronston LJ, Cass S, Chalian AA, Desmond AL, Earll JM, Fife TD, Fuller DC, Judge JO, Mann NR, Rosenfeld RM, Schuring LT, Steiner RWP, Whitney SL, Haidari J. Clinical practice guideline: Benign paroxysmal positional vertigo. *Otolaryngol Head Neck Surg* 2008;139:S47-S81.
9. Neuhauser HK, Lempert T. Vertigo: epidemiologic aspects. *Semin Neurol.* 2009;29(5):473-81.
10. Korres SG, Balatsouras DG, Ferekidis E. Electronystagmographic findings in benign paroxysmal positional vertigo. *Ann Otol Rhinol Laryngol.* 2004;113:313-18.
11. Parnes LS, McClure JA. Free-floating endolymph particles: a new operative finding during posterior semicircular canal occlusion. *Laryngoscope* 1992;102:988-992.
12. Schuknecht HF. Cupulolithiasis. *Arch Otolaryngol* 1969;90:113-26.
13. von Brevern M, Clarke AH, Lempert T. Continuous vertigo and spontaneous nystagmus due to canalithiasis of the horizontal canal. *Neurology* 2001;56:684-6.
14. Steenerson RL, Cronin GW, Marbach PM. Effectiveness of treatment techniques in 923 cases of benign paroxysmal positional vertigo. *Laryngoscope* 2005;115:226-31.

15. Korres S, Balatsouras D, Papouliakos S, Ferekidis SPE. Benign paroxysmal positional vertigo and its management. *Med Sci Monit.* 2007;13(6):CR275-82.
16. De La Meillure G, Dehaene I, Depondt M, Damman W, Crevits L, Vanhooren G. Benign Paroxysmal positional vertigo of the horizontal canal. *J Neurol Neurosurg Psychiatr.* 1996;60:68-71.
17. Herdman SJ, Tusa RJ. Complications of the repositioning procedure. *Arch Otolaryngol Head Neck Surg.* 1996;112(3):281-6.
18. Suzuki M, Yukawa K, Horiguchi S, Ichimura A, Kitamura K, Okamoto N, et al. Clinical features of paroxysmal positional vertigo presenting combined lesions. *Acta Otolaryngol.* 1999;119(2):117-20.
19. Imai T, Noriaki T, Ito M, Nakamae K, Sakae H, Fujioka, et al. Benign paroxysmal positional vertigo due to a simultaneous involvement of both horizontal and posterior semicircular canals. *Audiol Neurotol.* 2006;11:198-205.
20. Molina MI, López-Escámez JA, Zapata C, Vergara L. Monitoring of caloric response and outcome in patients with benign paroxysmal positional vertigo. *Otol Neurotol.* 2007;28:798-800.
21. Gacek RR. Pathology of benign paroxysmal positional vertigo revisited. *Ann Otol Rhinol Laryngol.* 2003;112:574-82.
22. Korres S, Balatsouras DG, Kaberos A, Economou C, Kandiloros D, Feredikis E. Occurrence of semicircular canal involvement in benign paroxysmal positional vertigo. *Otol Neurotol.* 2002;23:926-32.
23. Korres SG, Balatsouras DG. Diagnostic, pathophysiologic, and therapeutic aspects of benign paroxysmal positional vertigo. *Otolaryngol Head and Neck Surg.* 2004;131:438-44.
24. Honrubia V, Baloh RW, Harris MR, Jacobson KM. Paroxysmal positional vertigo syndrome. *Am J Otol.* 1999;20:465-70.
25. Chiou W, Lee H, Tsai S, Hsueh Y, Lee X. A single therapy for all subtypes of horizontal canal positional vertigo. *Laryngoscope* 2005;115:1432-5.
26. De la Meillure G, Dehaene I, Depondt M, Dammam W, Crevits L, Vanhooren G. Benign paroxysmal positional vertigo of the horizontal canal. *J Neurol Neurosurg Psychiatry.* 1996 Jan;60(1):68-71.
27. Lee SH, Kim MK, Cho KH, Kim JS. Reversal of initial positioning nystagmus in benign paroxysmal positional vertigo involving the horizontal canal. *Ann N Y Acad Sci.* 2009 May;1164:406-8.
28. Gross EM, Ress BD, Viirre ES, Nelson JR, Harris JP. Intractable benign paroxysmal positional vertigo in patients with Ménière's disease. *Laryngoscope* 2000;110:655-9.
29. Kalberg M, Hall K, Quickert N, Hinson J, Halmagy GM. What inner ear diseases cause benign paroxysmal positional vertigo? *Acta Otolaryngol.* 2000;120:380-5.
30. Hughes CA, Proctor L. Benign paroxysmal positional vertigo. *Laryngoscope* 1997;107:607-13.
31. Boaglio M, Soares LCA, Ibrahim CSMN, Ganança FF, Cruz OLM. Doença de Ménière e vertigem postural. *Braz J Otorhinolaryngol.* 2003;69(1):69-72.
32. Giacomini PG, Napolitano B, Alessandrini M, Di Girilamo S, Magrini A. Recurrent paroxysmal positional vertigo related to oral contraceptive treatment. *Gynecol Endocrinol.* 2006;22(1):5-8.
33. Dornhoffer JL, "kiP" Colvin GB. Benign paroxysmal positional vertigo and canalith repositioning: clinical correlations. *Am J Otol.* 2000;21:230-3.
34. Jang YS, Hwang CH, Shin JY, Bae WY, Kim LS. Age-related changes on the morphology of the otoconia. *Laryngoscope.* 2006;116:996-1001.
35. Katsarkas A. Paroxysmal positional vertigo: an overview and the deposits repositioning maneuver. *Am J Otol.* 1995;16(6):725-30.
36. Katsarkas A. Eletronytagmographic (ENG) findings in paroxysmal positional vertigo (PPV) as a sign of vestibular dysfunction. *Acta Otolaryngol.* 1991;111:193-200.
37. Blakely BW. A randomized, controlled assessment of the canalith repositioning maneuver. *Otolaryngol Head Neck Surg.* 1994;110:391-6.
38. Assawavichianginda S, Isipradit P, Snidvong K, Supiyaphun P. Canalith repositioning for benign paroxysmal positional vertigo: a randomized controlled trial. *Ear Nose Throat J.* 2000;30:732-8.
39. Epley J. The canalith repositioning procedure for treatment of benign paroxysmal positional vertigo. *Otolaryngol Head Neck Surg.* 1992;107:399-404.
40. Brandt T, Steddin S, Eng D. Therapy for benign paroxysmal positioning vertigo, revisited. *Neurology.* 1994;44:796-800.
41. Semont A, Freyss E, Vitte P. Curing the BPPV with a liberatory maneuver. *Adv Otorhinolaryngol.* 1988;4:290-93.
42. Lempert T. Horizontal benign positional vertigo. *Neurology* 1994;44(11):2213-4.
43. Lempert T, Tiel-Wilck K. A positional maneuver for treatment of horizontal-canal benign paroxysmal positional vertigo. *Laryngoscope.* 1996;106:476-8.
44. Vannucchi P, Giannoni B, Pagnini P. Treatment of horizontal semicircular canal benign paroxysmal positional vertigo. *J Vestib Res.* 1997;7:1-6.
45. Çelebisoy N, Bayam E, Guleç F, Kose T, Akyureli O. Balance in posterior and horizontal canal type benign paroxysmal positional vertigo before and after repositioning maneuvers. *Gait & Posture* 2009;29:520-523.
46. Di Girolamo S, Ottaviani F, Scarano E, Picciotti P, Di Nardo W. Postural control in horizontal benign paroxysmal positional vertigo. *Eur Arch Otorhinolaryngol* 2000;257:372-375.
47. Gans RE, Harrington-Gans PA. Treatment efficacy of benign paroxysmal positional vertigo (BVVP) with canalith repositioning maneuver and Semont liberatory maneuver in 376 patients. *Seminars in hearing.* 2002;23(2):129-42.
48. Epley JM. Human experience with canalith repositioning maneuvers. *Ann N Y Acad Sci.* 2001;942:179-191.
49. Appiani GC, Catania G, Gagliardi M. A liberatory maneuver for the treatment of horizontal canal paroxysmal positional vertigo. *Otol Neurotol.* 2001;22:66-9.
50. Baloh, RW, Honrubia V. Clinical neurophysiology of the vestibular system. Third edition. Oxford University Press 2001.
51. Oh HJ, Kim JS, Han BI, Lim JG. Predicting a successful treatment in posterior canal benign paroxysmal positional vertigo. *Neurology* 2007;68:1219-22.
52. Nuti D, Nati C, Passali D. Treatment of benign paroxysmal positional vertigo: no need for post-maneuver restrictions. *J Otolaryngol.* 2000;122:440-4.
53. Roberts RA, Gans RE, DeBoodt JL, Lister JJ. Treatment of benign paroxysmal positional vertigo: necessity of postmaneuver patient restrictions. *J Am Acad Audiol.* 2005;16(6):357-66.
54. Simoceli L, Bittar RS, Greters ME. Posture restrictions do not interfere in the results of canalith repositioning maneuver. *Braz J Otorhinolaryngol.* 2005;71(1):55-9.
55. Motamed M, Osinubi O, Cook JA. Effect of mastoid oscillation on the outcome of the canalith repositioning procedure. *Laryngoscope* 2004;114(7):1296-8.
56. Macias JD, Ellensohn A, Massingale S, Gerkin R. Vibration with the canalith repositioning maneuver: a prospective randomized study to determine efficacy. *Laryngoscope* 2004;114(6):1011-4.
57. Ruckenstein MJ, Shepard NT. The canalith repositioning procedure with and without mastoid oscillation for the treatment of benign paroxysmal positional vertigo. *ORL J Otorhinolaryngol Relat Spec.* 2007;69(5):295-8.
58. Herdman SJ, Tusa RJ, Zee DS, Proctor LR, Mattox DE. Single treatment approaches to benign paroxysmal positional vertigo. *Arch Otolaryngol Head Neck Surg.* 1993;119(4):450-4.
59. Furman J, Cass S. Benign paroxysmal positional vertigo. *N Engl J Med.* 1999;341:1590-6.
60. Lynn S, Pool A, Rose D, Brey R, Suman V. Randomized trial of the canalith repositioning procedure. *Otolaryngol Head Neck Surg.* 1995;113(6):712-20.

-
61. Blakley BW. Canalith repositioning procedure. *Otolaryngol Head Neck Surg.* 1996;114(3):503-5.
 62. Zucca G, Valli S, Valli P, Perin P, Mira E. Why do benign paroxysmal positional vertigo episodes recover spontaneously? *J Vestib Res.* 1998;8:325-9.
 63. Imai T, Ito M, Takeda N, Uno A, Matsunaga T, Sekine K, et al. Natural course of the remission of vertigo in patients with benign paroxysmal positional vertigo. *Neurology* 2005;64:920-1.
 64. Sekine K, Imai T, Sato G, Ito M, Takeda N. Natural history of benign paroxysmal positional vertigo and efficacy of Epley and Lempert maneuvers. *Otolaryngol Head Neck Surg.* 2006;135:529-33.
 65. Crevitis L. Treatment of anterior canal benign paroxysmal positional vertigo by a prolonged forced position procedure. *J Neurol Neurosurg Psychiatry.* 2004;75:779-81.
 66. Buttner U, Helmchen CH, Brandt TH. Diagnostic criteria for central versus peripheral positioning nystagmus and vertigo: a review. *Acta Otolaryngol (Stockh).* 1999;119:1-5.